



AMLI II
ATHENS MEDICAL
LEADERSHIP + INNOVATION
CONFERENCE



**ATHENS MEDICAL
GROUP**

Always one step ahead!

35
YEARS
OF EXCELLENCE

23-25 November 2018

Megaron Athens International Conference Center

www.iatriko.gr

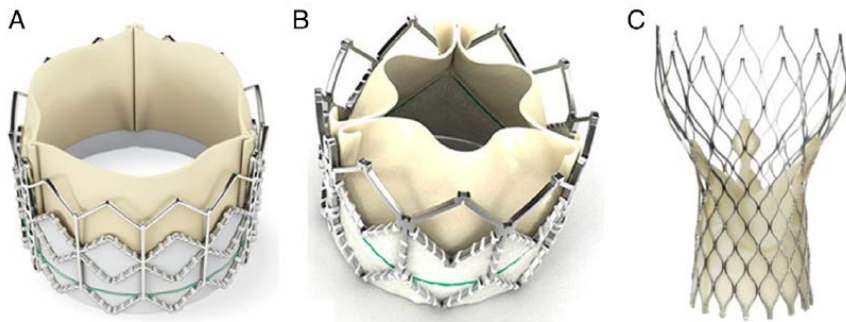


Figure 1 Current Widely Available Transcatheter Valves

(A) The Edwards SAPIEN THV balloon-expandable valve (Edwards Lifesciences, Irvine, California) incorporates a stainless steel frame, bovine pericardial leaflets, and a fabric sealing cuff. (B) The SAPIEN XT THV (Edwards Lifesciences) utilizes a cobalt chromium alloy frame and is compatible with lower profile delivery catheters. (C) The Medtronic CoreValve (Medtronic, Minneapolis, Minnesota) incorporates a self-expandable frame, porcine pericardial leaflets, and a pericardial seal.

Update in Transcatheter Aortic Valve Implantation

Georgios I. Papaioannou, MD, MPH, FACC, FSCAI

Director, Interventional Cardiologist

Athens Medical Center

Cardiac Catheterization Laboratory

23/11/2018

AMLI II 23-25/11/2018

Centers of Excellence

Digital Transformation

Personalized Medicine

Redefining Longevity

Cross Border Healthcare

Science & Technology

Collaboration with



The Research Institute for Longevity
and Prevention of Aging-Related Diseases




AMLI II
ATHENS MEDICAL
LEADERSHIP + INNOVATION
CONFERENCE



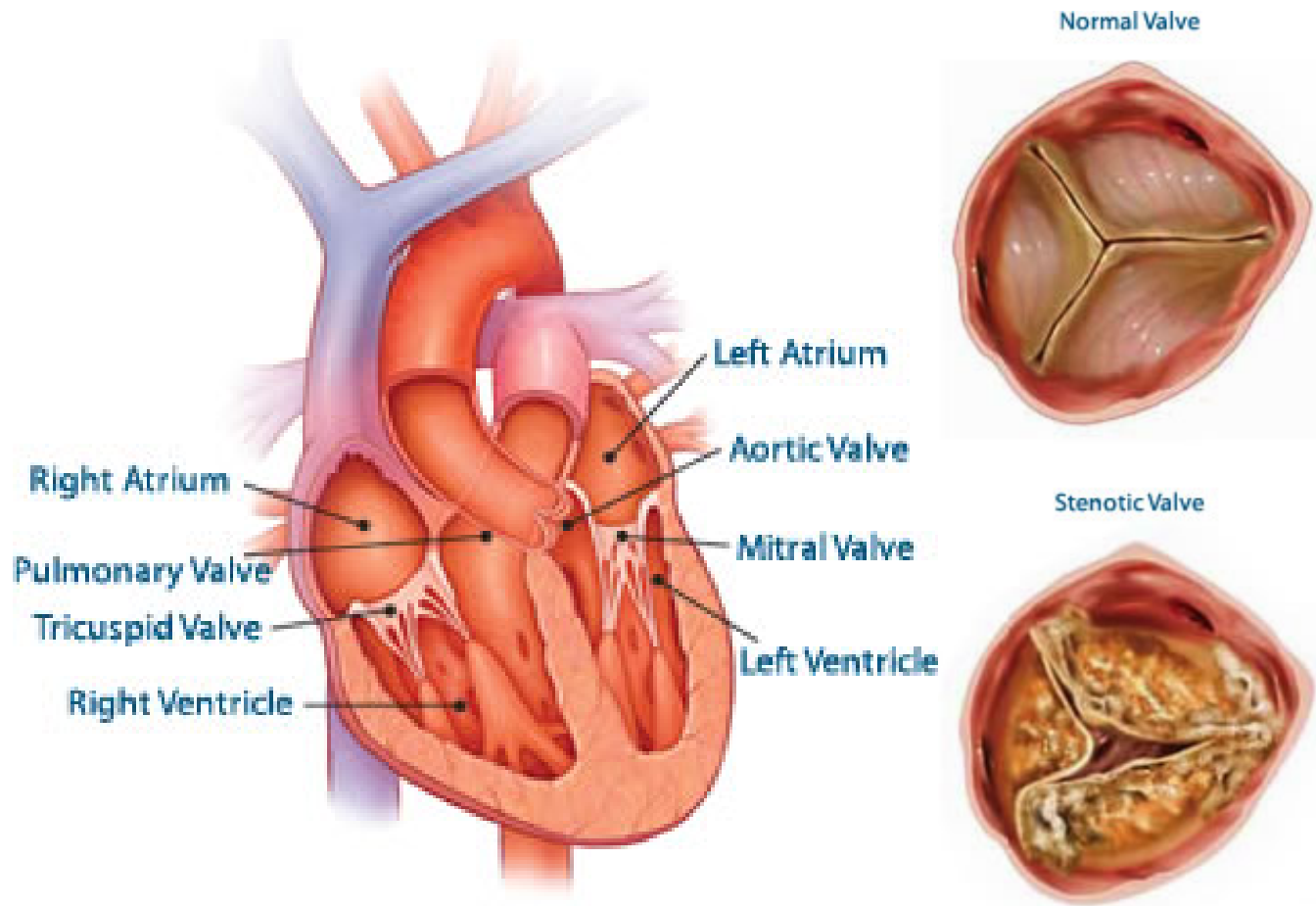
**ATHENS MEDICAL
GROUP**

Always one step ahead!

35
YEARS
OF EXCELLENCE

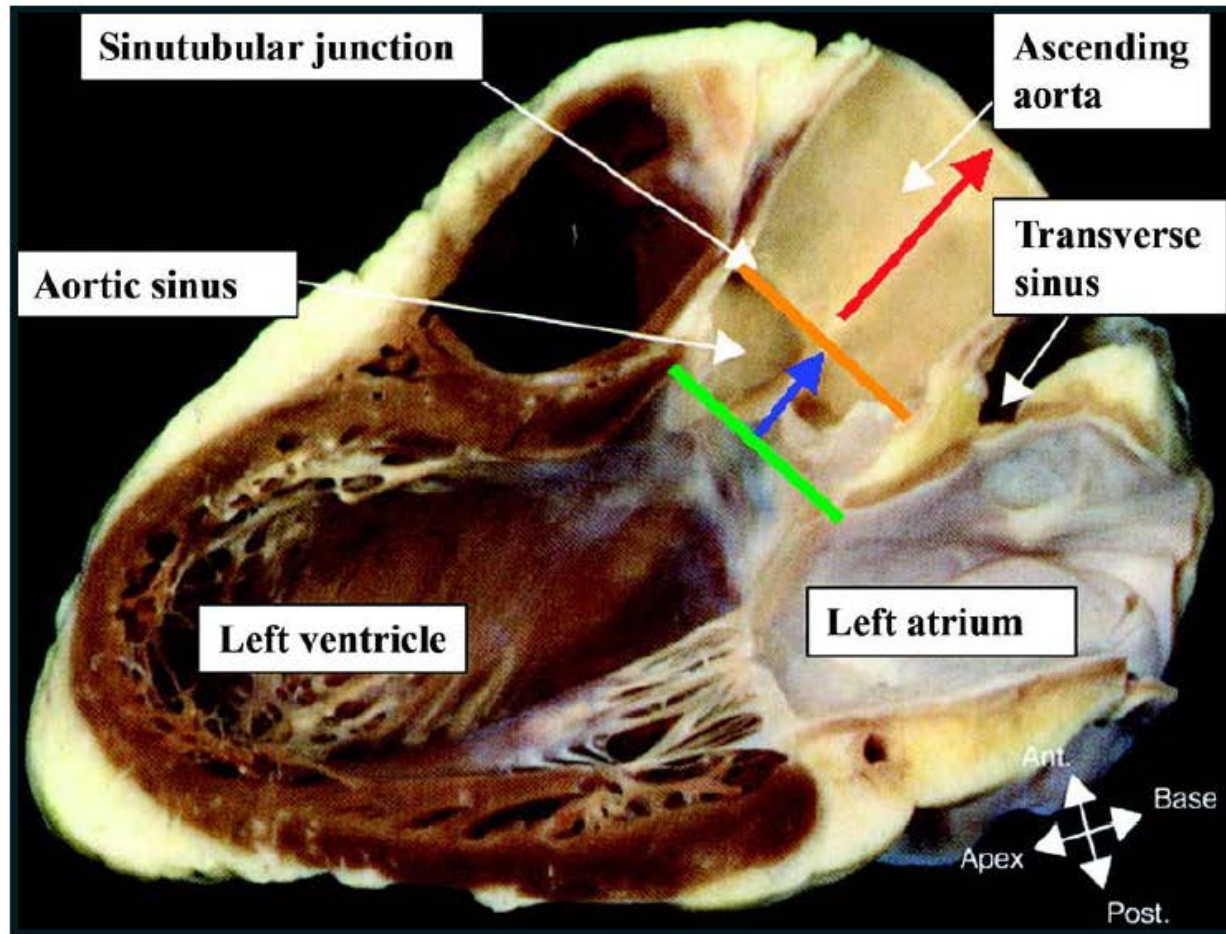


Aortic Valve Anatomy



Aortic Root Anatomy

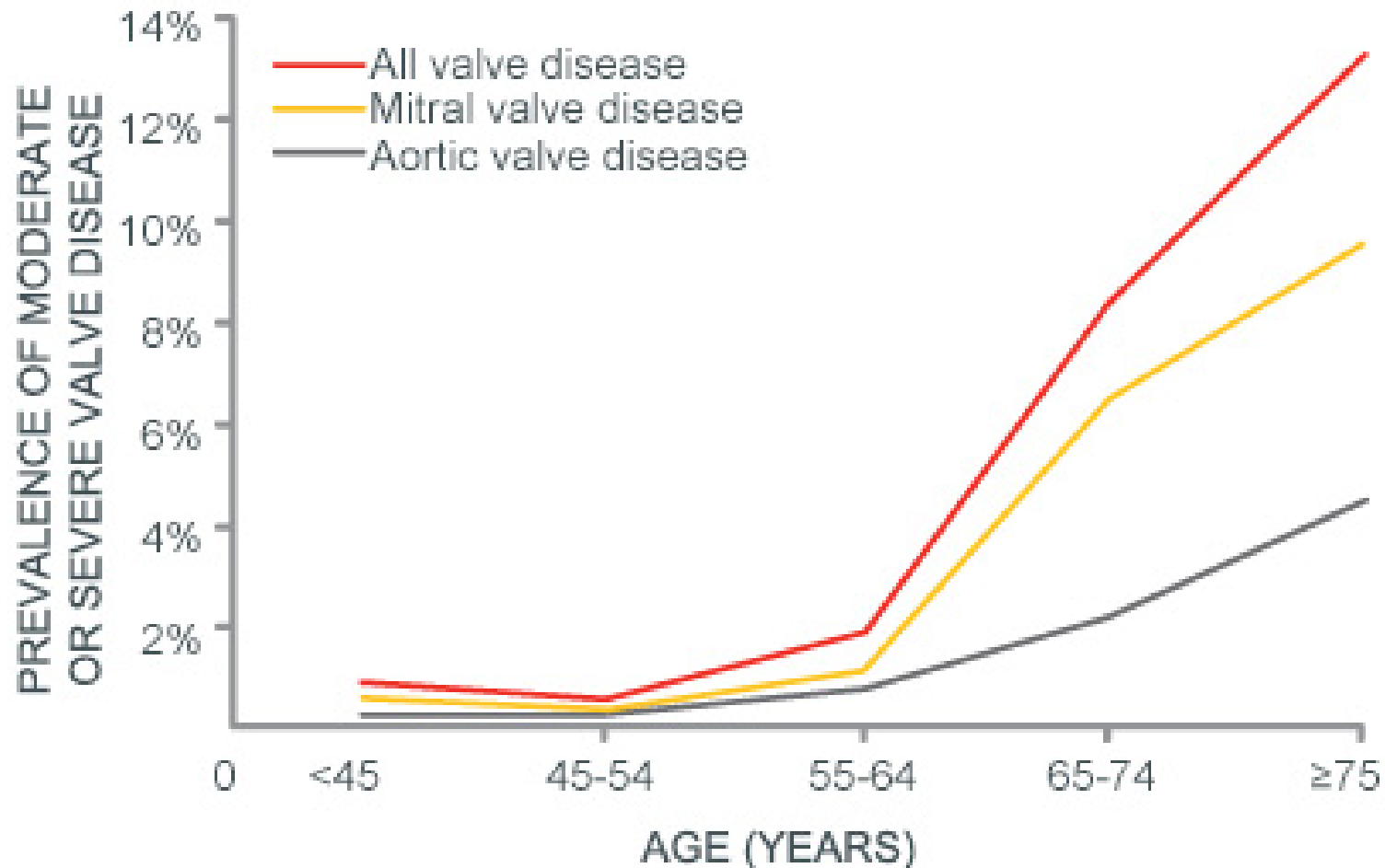
Aortic Root Anatomic Overview



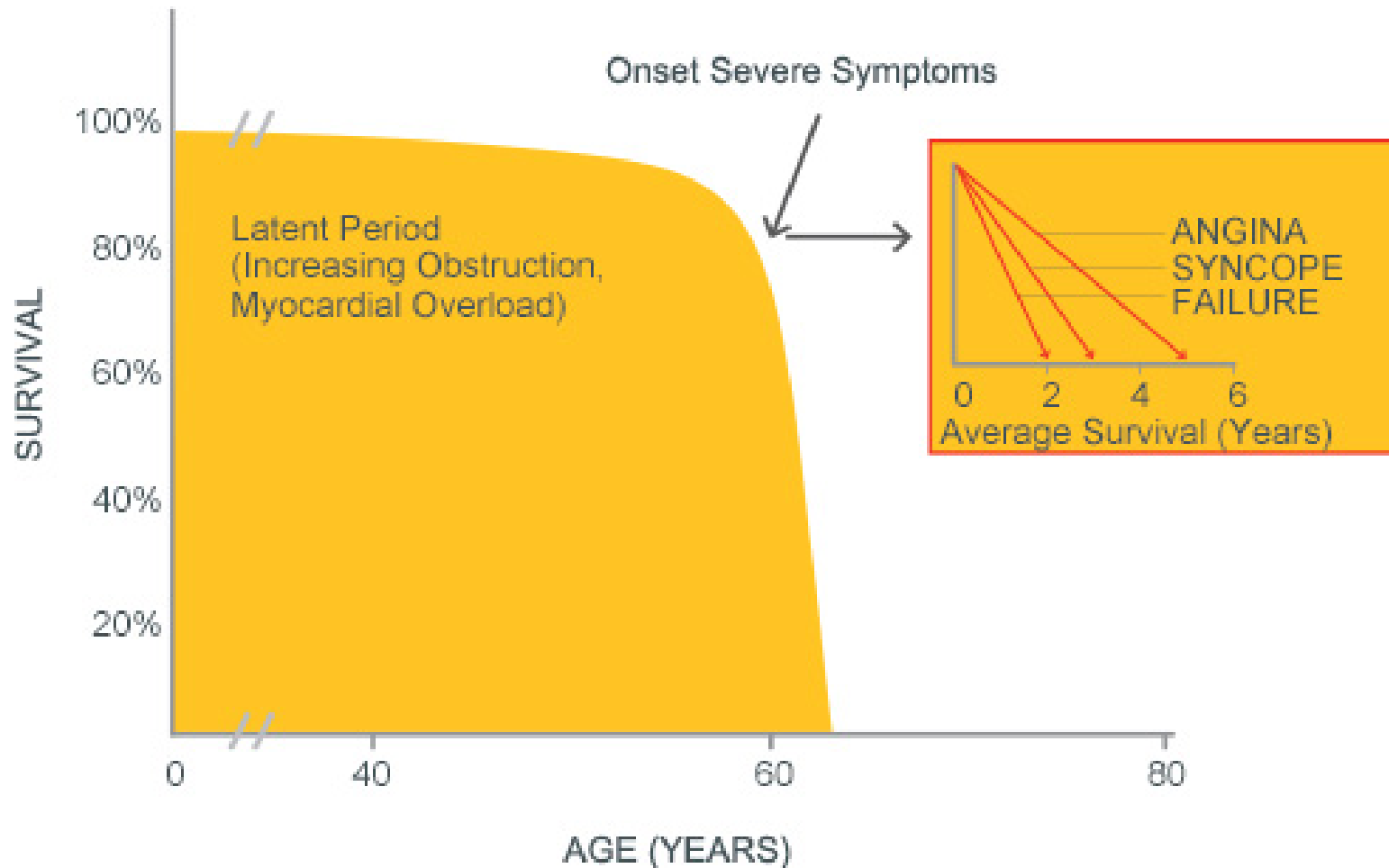
Causes of Aortic Stenosis

- Age related-Annular Calcification
- History of Rheumatic Fever
- Congenital Anomalies (Bicuspid Valve)
- History of Chest Radiation
- Autoimmune Diseases
- Congenital Hypercholesterolemia
- End-stage Renal Disease

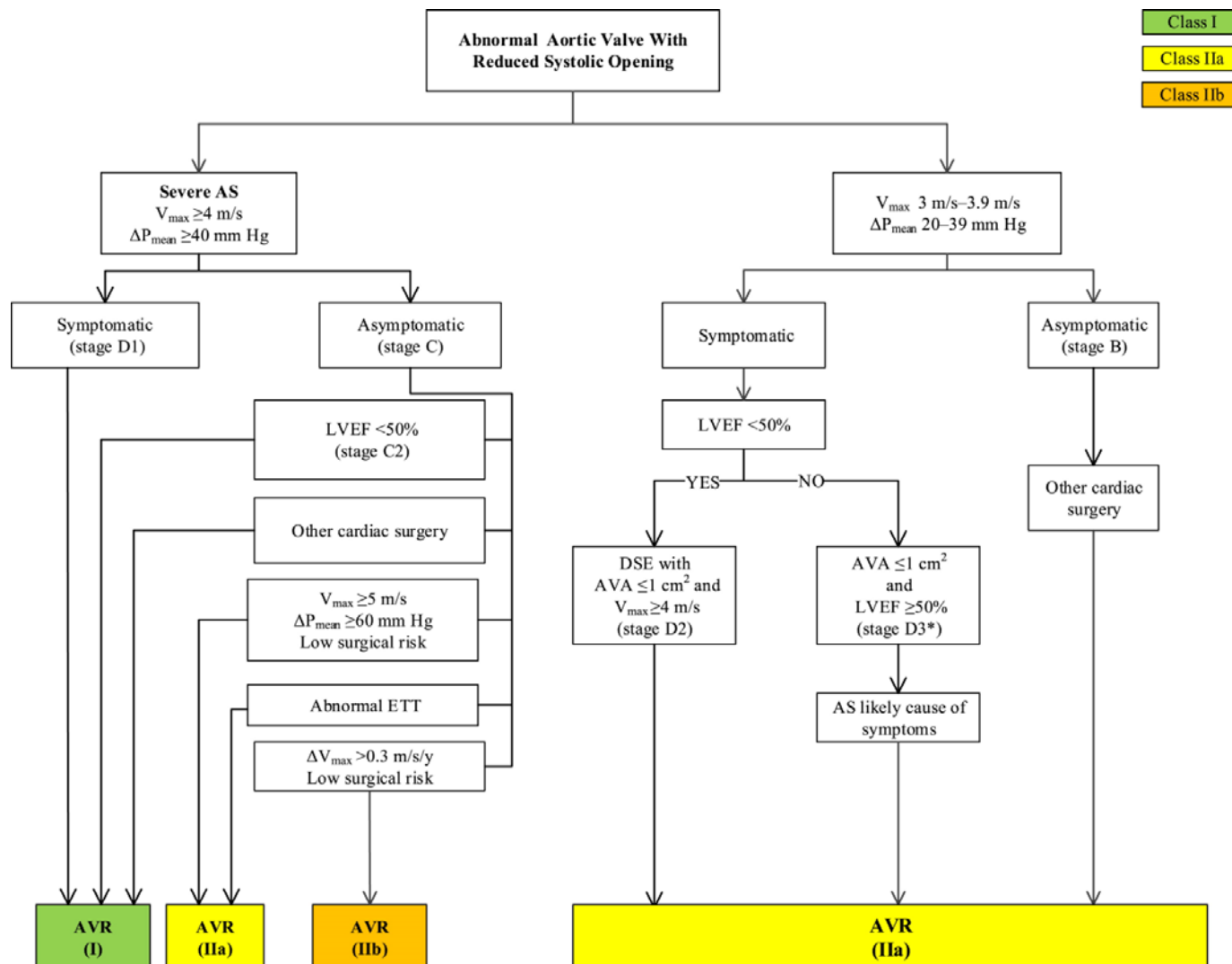
Incidence of Aortic and Mitral Valve Disease



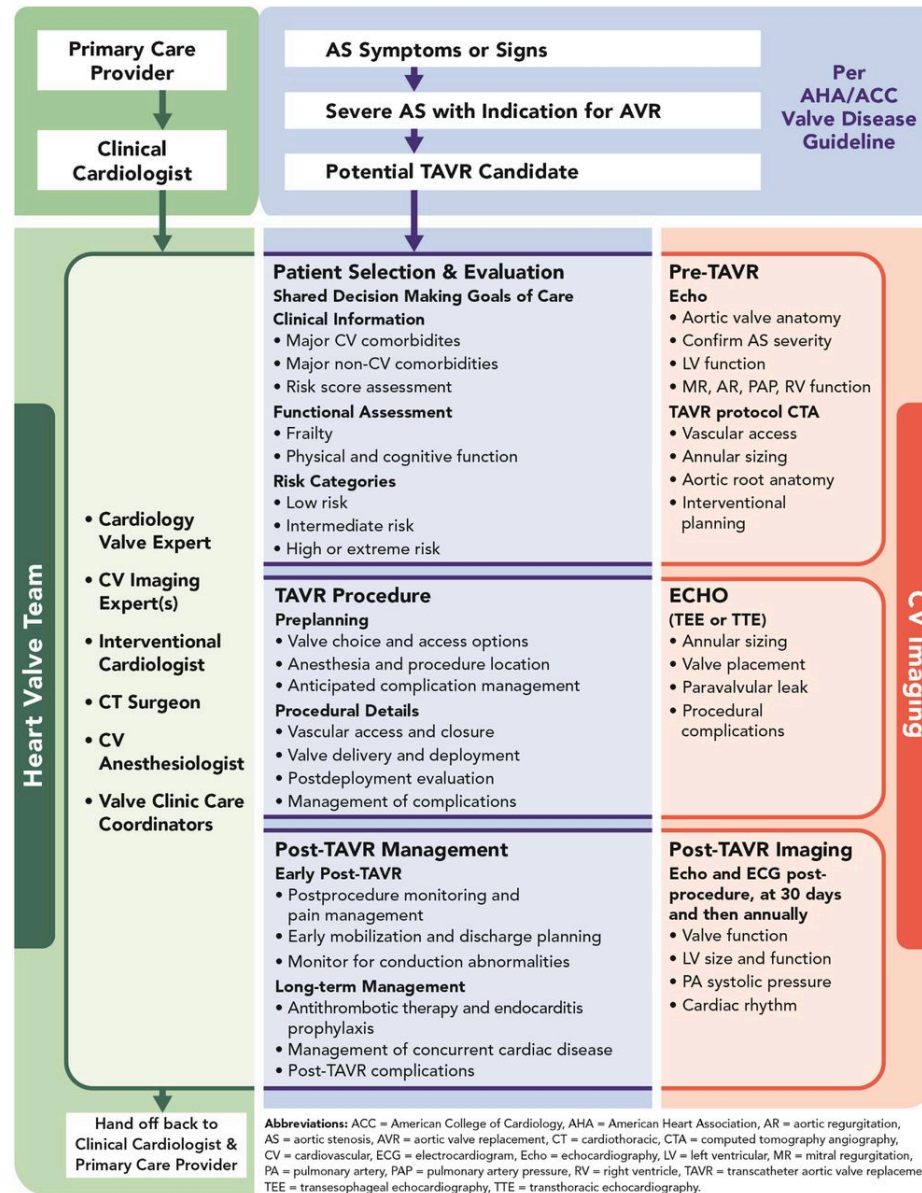
Natural History and Symptoms of Aortic Stenosis



Aortic Stenosis Treatment Algorithm






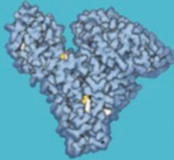
TAVI Decision Pathway



Risk Assessment (STS/Frailty/Comorbidities/Procedure specific issues)

- **1. Low risk:** STS <4% with no frailty, no comorbidity, and no procedure-specific impediments.
- **2. Intermediate risk:** STS 4% to 8% with no more than mild frailty or 1 major organ system compromise not to be improved postoperatively, and minimal procedure-specific impediments.
- **3. High risk:** STS >8%, or moderate-severe frailty, no more than 2 major organ system compromise not to be improved postoperatively, or a possible procedure-specific impediment.
- **4. Prohibitive risk:** Preoperative risk of mortality and morbidity >50% at 1 year, ≥3 major organ system compromise not to be improved postoperatively, severe frailty, or severe procedure-specific impediments.

Frailty Index

	Five chair rises <15 seconds	0 Points
	Five chair rises ≥15 seconds	1 Point
	Unable to complete	2 Points
	No cognitive impairment	0 Points
	Cognitive impairment	1 Point
	Hemoglobin ≥13.0 g/dL ♂ ≥12.0 g/dL ♀	0 Points
	Hemoglobin <13.0 g/dL ♂ <12.0 g/dL ♀	1 Point
	Serum albumin ≥3.5 g/dL	0 Points
	Serum albumin <3.5 g/dL	1 Point

EFT Score	1-Year Mortality	
	TAVR	SAVR
0-1	6%	3%
2	15%	7%
3	28%	16%
4	30%	38%
5	65%	50%

EFT Points: _____

PARTNER 1A-2 year Results

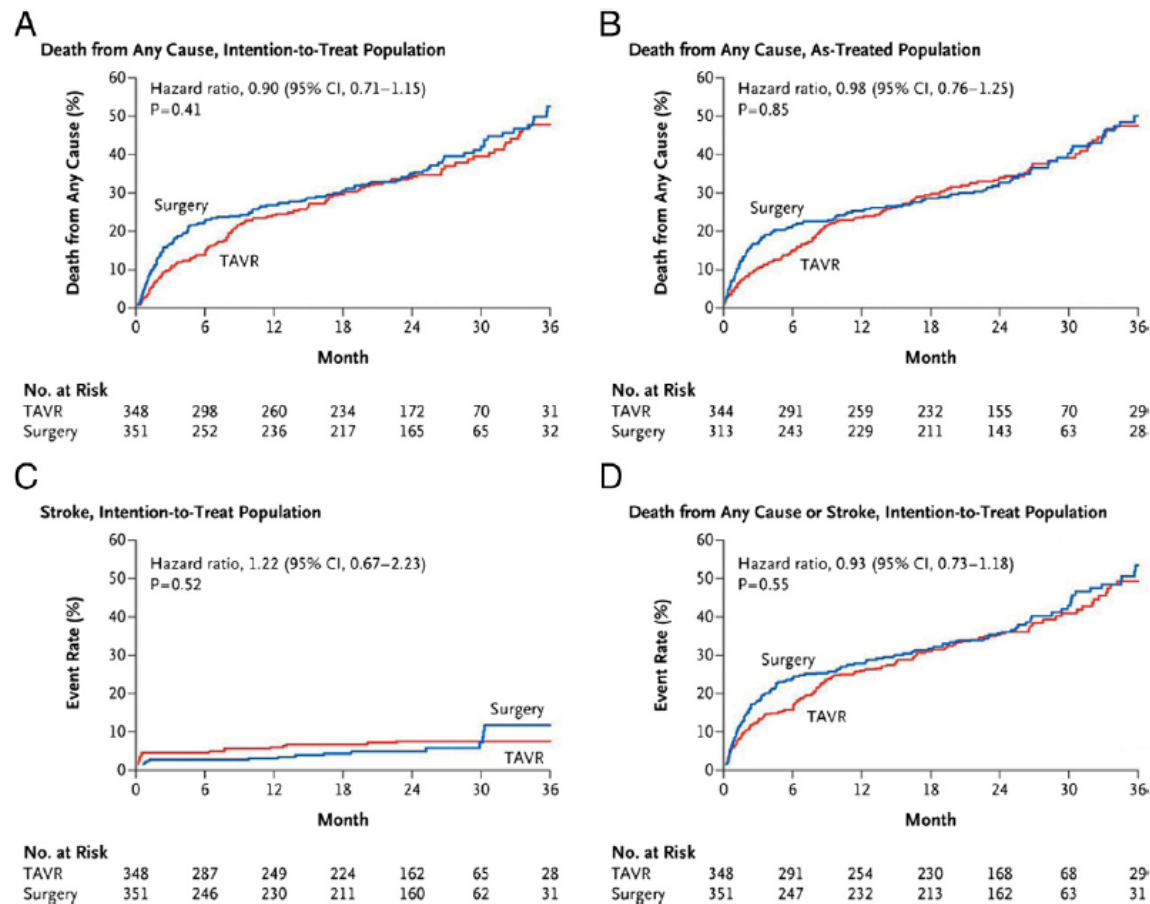


Figure 7 The PARTNER 1A 2-Year Outcomes After Transcatheter or Surgical Aortic Valve Replacement

Kaplan-Meier time-to-event curves are shown for death by intention to treat (**A**) and as-treated (**B**), stroke (**C**), and the composite of death or stroke (**D**). Mortality and stroke rates were similar. Reprinted from Smith CR, Leon MB, Mack MJ, et al. Transcatheter versus surgical aortic-valve replacement in high-risk patients. *N Engl J Med* 2011;364:2187-98, with the permission of the Massachusetts Medical Society. PARTNER = Placement of AoTic TraNscathetER Valve.

PARTNER 1B-Extremely High Risk Pts

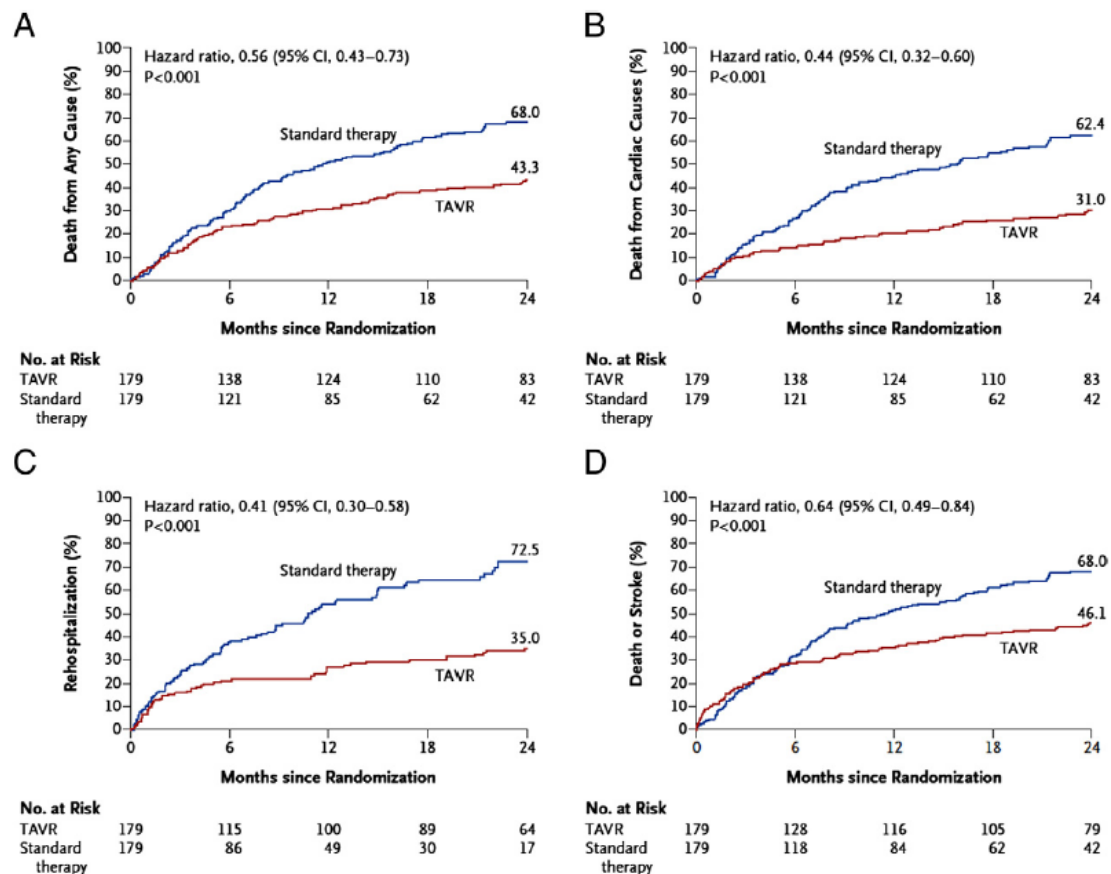


Figure 6 The PARTNER 1B Trial Compared Transarterial TAVR to Medical Management in Extremely High-Risk (Inoperable) Patients

Time to event analyses of death (A), death due to cardiac causes (B), rehospitalization (C), and the combined endpoint of death or stroke (D). Redrawn from Leon MR, Smith CR, Mack M, et al. Transcatheter aortic-valve implantation for aortic stenosis in patients who cannot undergo surgery. *N Engl J Med* 2010;363:1597–607, with information from Makkar RR, Fontana GP, Jilaihawi H, et al. Transcatheter aortic-valve replacement for inoperable severe aortic stenosis. *N Engl J Med* 2012;366:1696–704, with permission from the Massachusetts Medical Society. PARTNER = Placement of AoRTic TraNscathetER Valve; TAVR = transcatheter aortic valve replacement.

US CoreValve Trial

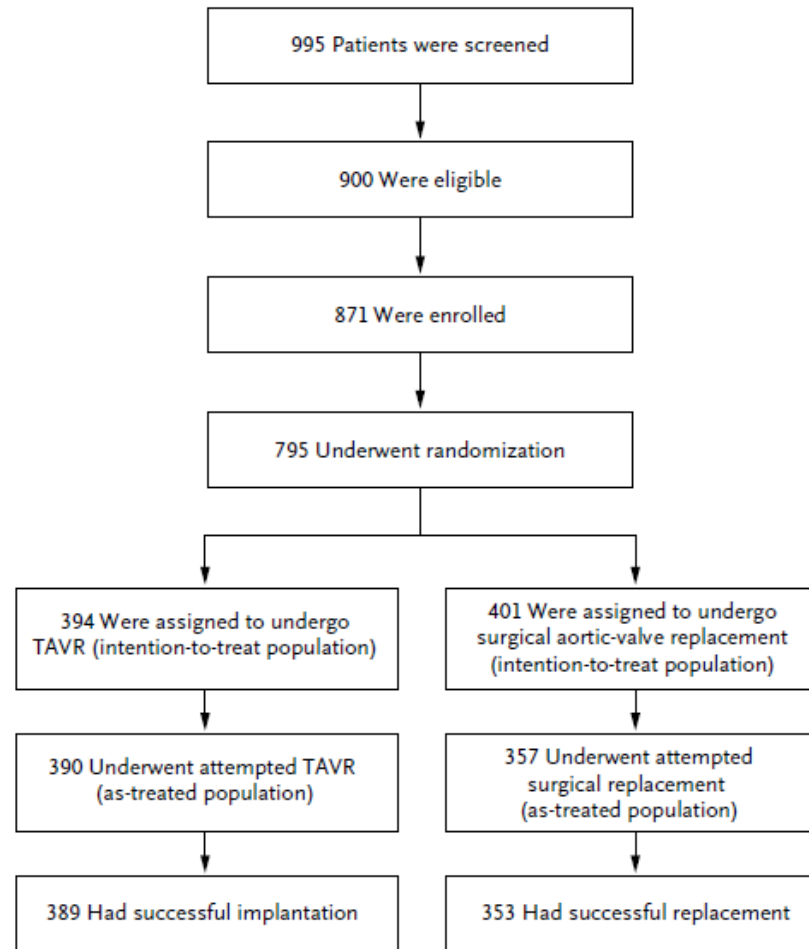
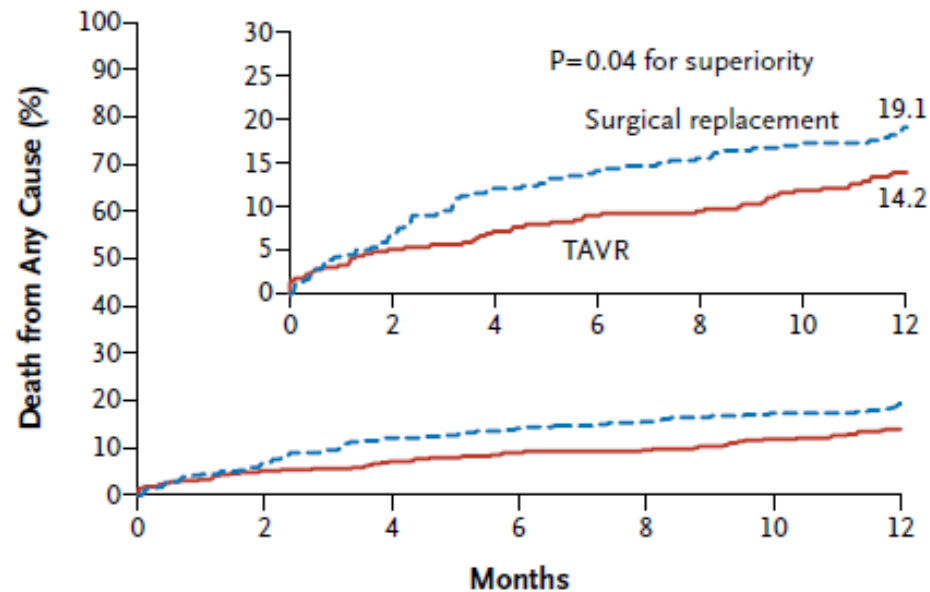


Figure 1. Randomization and Analysis Populations.

TAVR denotes transcatheter aortic-valve replacement.

US CoreValve Trial



No. at Risk

TAVR	390	377	353	329
Surgical replacement	357	341	297	274

Figure 2. Kaplan–Meier Cumulative Frequency of Death from Any Cause.

The rate of death from any cause in the TAVR group was noninferior to that in the surgical group ($P < 0.001$). A subsequent test for superiority at 1 year showed that TAVR was superior to surgical replacement ($P = 0.04$). The inset shows the same data on an enlarged y axis.

US CoreValve Trial-Complications

Table 2. Procedural Outcomes at 30 Days and 1 Year in the As-Treated Population.*

Outcome	30 Days			1 Year		
	TAVR Group (N=390)	Surgical Group (N=357)	P Value	TAVR Group (N=390)	Surgical Group (N=357)	P Value
	<i>number (percent)</i>			<i>number (percent)</i>		
Major vascular complication	23 (5.9)	6 (1.7)	0.003	24 (6.2)	7 (2.0)	0.004
Bleeding event†						
Life-threatening or disabling bleeding	53 (13.6)	125 (35.0)	<0.001	64 (16.6)	136 (38.4)	<0.001
Major bleeding	109 (28.1)	123 (34.5)	0.05	114 (29.5)	130 (36.7)	0.03
Acute kidney injury	23 (6.0)	54 (15.1)	<0.001	23 (6.0)	54 (15.1)	<0.001
Cardiogenic shock	9 (2.3)	11 (3.1)	0.51	9 (2.3)	11 (3.1)	0.51
Cardiac perforation	5 (1.3)	0	0.03	5 (1.3)	0	0.03
Permanent pacemaker implantation	76 (19.8)	25 (7.1)	<0.001	85 (22.3)	38 (11.3)	<0.001
New-onset or worsening atrial fibrillation	45 (11.7)	108 (30.5)	<0.001	60 (15.9)	115 (32.7)	<0.001

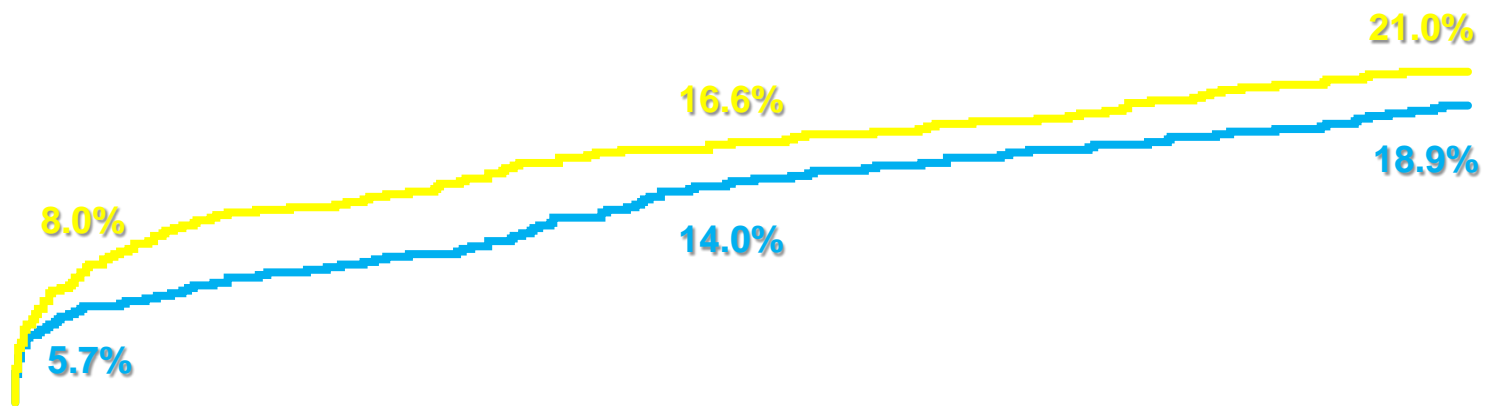
Primary Endpoint-PARTNER 2A-Intermediate Risk

All-Cause Mortality or Disabling Stroke (N Engl J Med 2016;374:1609-20)

1

— Surgery
— TAVR

p (log rank) = 0.180

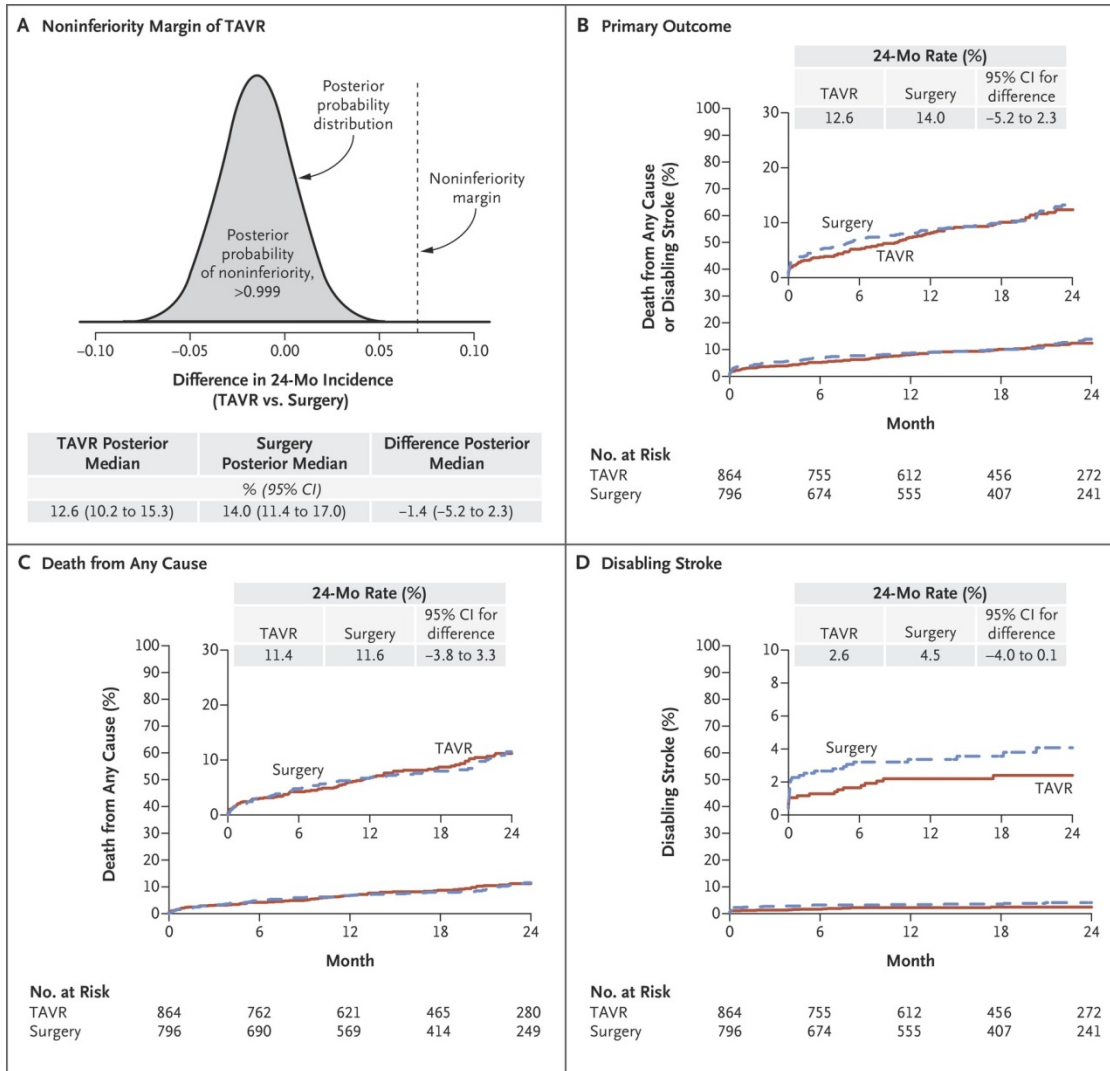


Surgery	944	826	807	779	766	743	731	715	694
TAVR	994	917	900	870	842	825	811	801	774

AMLI II 23-25/11/2018

SURTAVI-CoreValve Trial in Intermediate Risk Patients

(J Am Coll Cardiol 2017;70:252-89)



Choice of Surgical or Transcatheter Treatment of AS

Recommendations	Class	LOE
Surgical AVR in low risk patients	I	A
TAVI or high-risk Surgery should be performed under Heart Team Guidance	I	C
TAVI for extremely high-risk patients + post TAVI predicted survival > 12 months	I	B
TAVI for high-risk and intermediate-risk patients	I (high-risk) – I (Interm risk ESC) – IIa (Interm Risk ACC)	B
BAV as a bridge to TAVI or SAVR	IIb	C
TAVI not recommended in patients with comorbidities which preclude benefit	III	B

TAVI Candidates

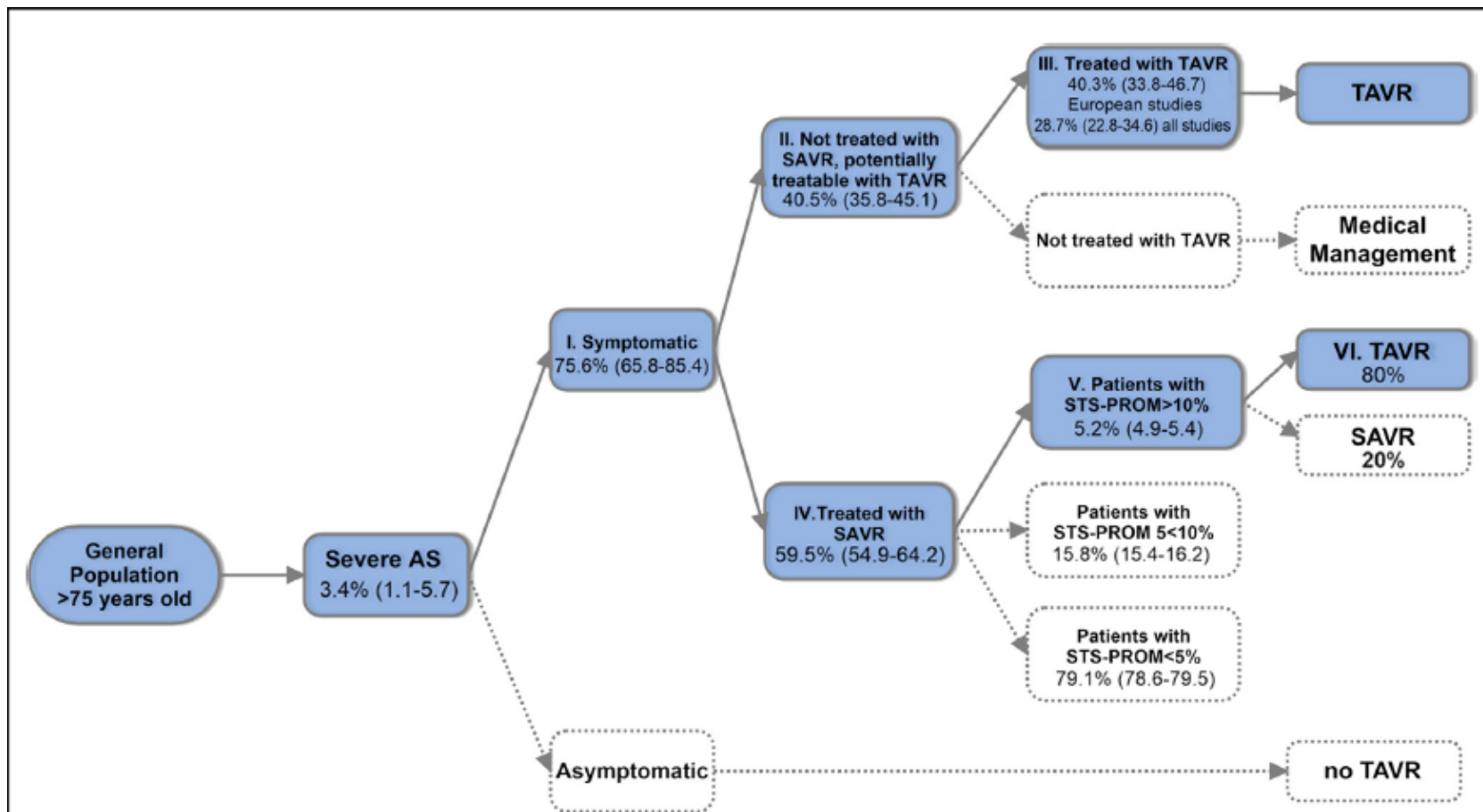
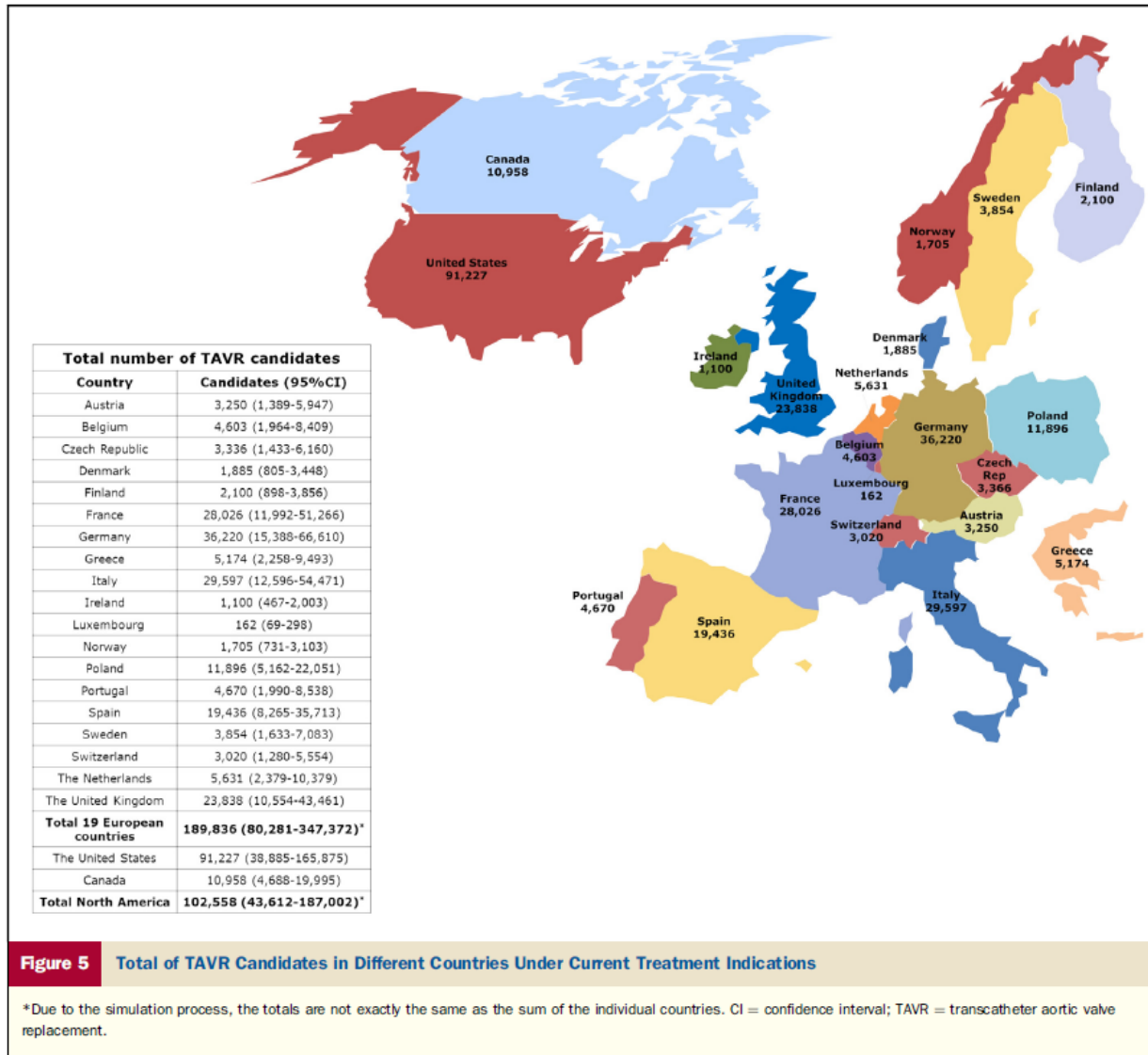


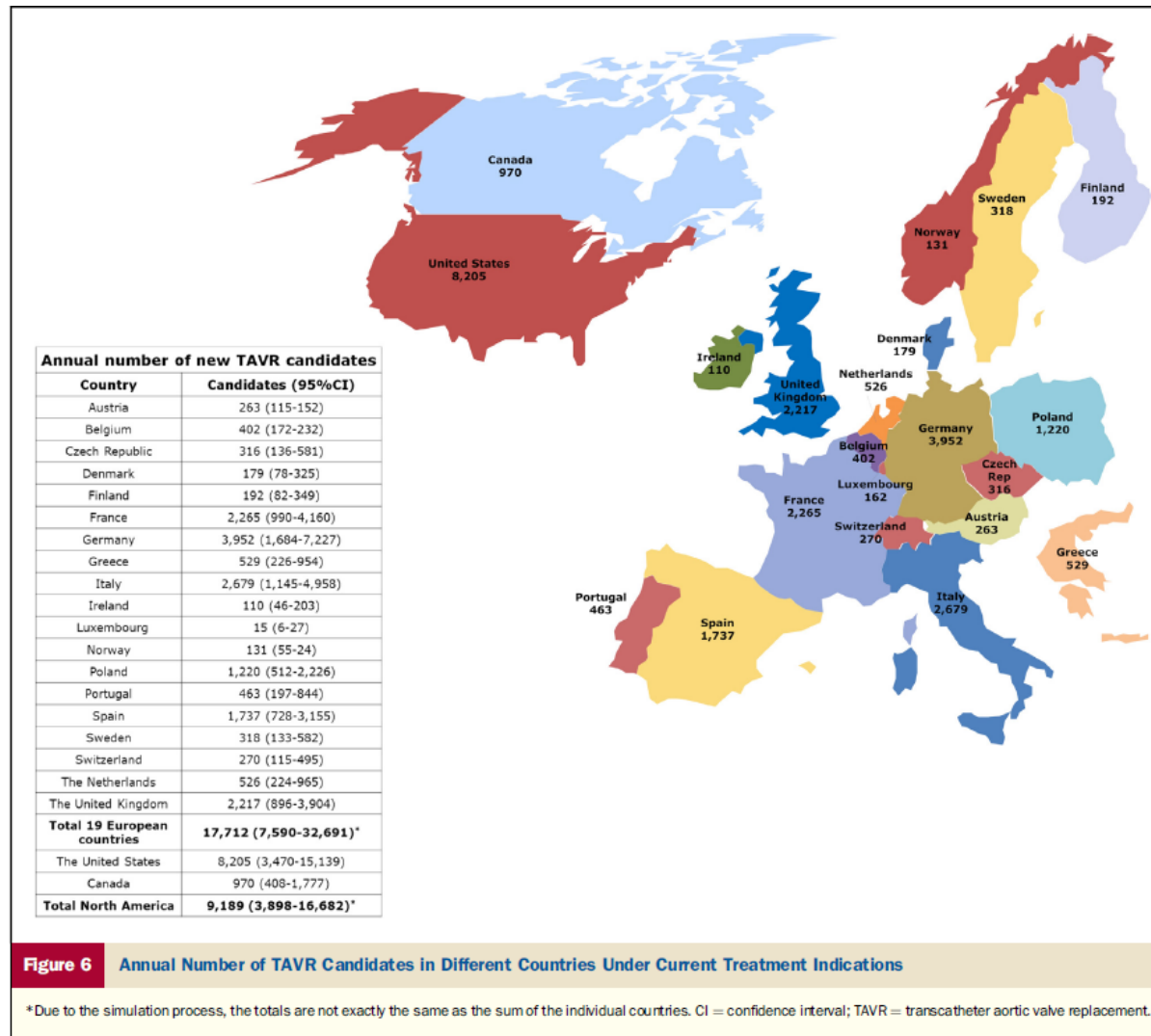
Figure 3 Model for the Estimation of TAVR Candidates Among the Elderly

AS = aortic stenosis; SAVR = surgical aortic valve replacement; STS-PROM = The Society of Thoracic Surgery Predicted Risk of Mortality; TAVR = transcatheter aortic valve replacement.

Worldwide TAVI Candidates



Worldwide TAVI Incidence Candidates



Edwards Sapien to Sapien XT to Sapien 3 and Centera self-expanding valve



Figure 2. Sapien XT Valve Features

(A) Size 26 Sapien XT made of 2 rows of metal cells (1 and 2). (B) Size 29 Sapien XT made of 3 rows of metal cells (1, 2, and 3). (C) Sapien XT size 29 under fluoroscopy. Arrows point to the level of the nadir of the leaflets. Row 1 is not covered by the fabric across all sizes.

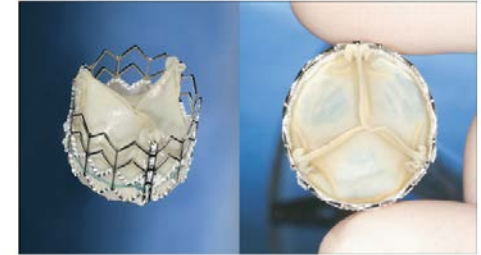

Figure 1. Profile of the Edwards SAPIEN Transcatheter Heart Valve

The Edwards SAPIEN transcatheter aortic prosthesis is mounted on a balloon-expandable stainless steel stent that is placed in the subcoronary position. The trileaflet bovine pericardial prosthesis is attached to the stent and treated with an anticalcification treatment. The stent has a polyethylene terephthalate fabric skirt that decreases perivalvular leaks.

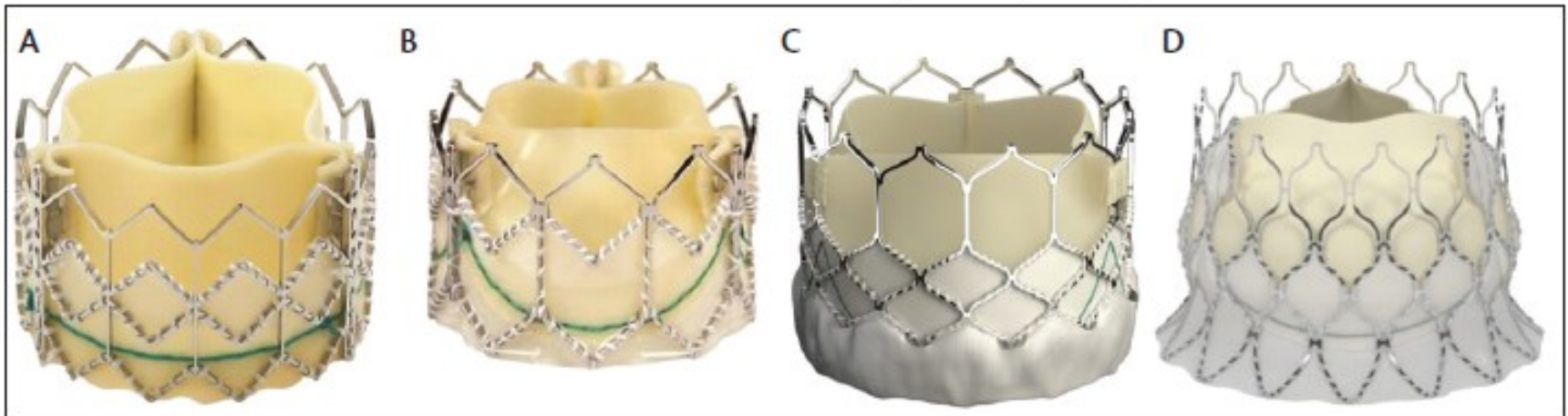


Figure 1. Sapien valve (A); Sapien XT valve (B); Sapien 3 valve (C); Centera valve (Edwards Lifesciences) (D).

CoreValve to Evolut R to Evolut Pro

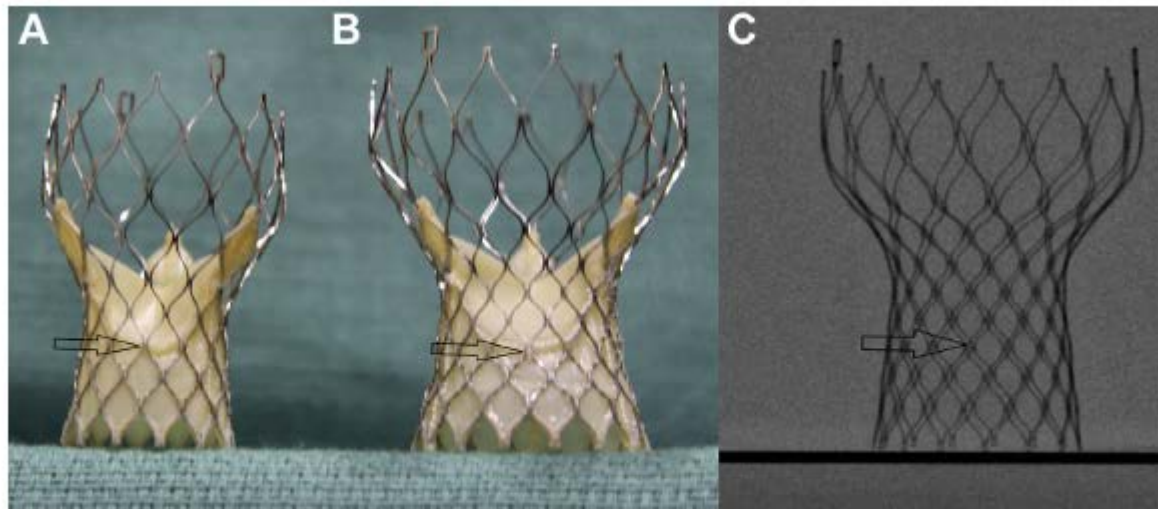


Figure 3. Evolute and CoreValve Features

(A) Evolute size 23; (B) CoreValve size 29; and (C) CoreValve size 29 under fluoroscopy. The **arrows** point to the third node, which corresponds to the nadir of the pericardial leaflets.

OtherValves

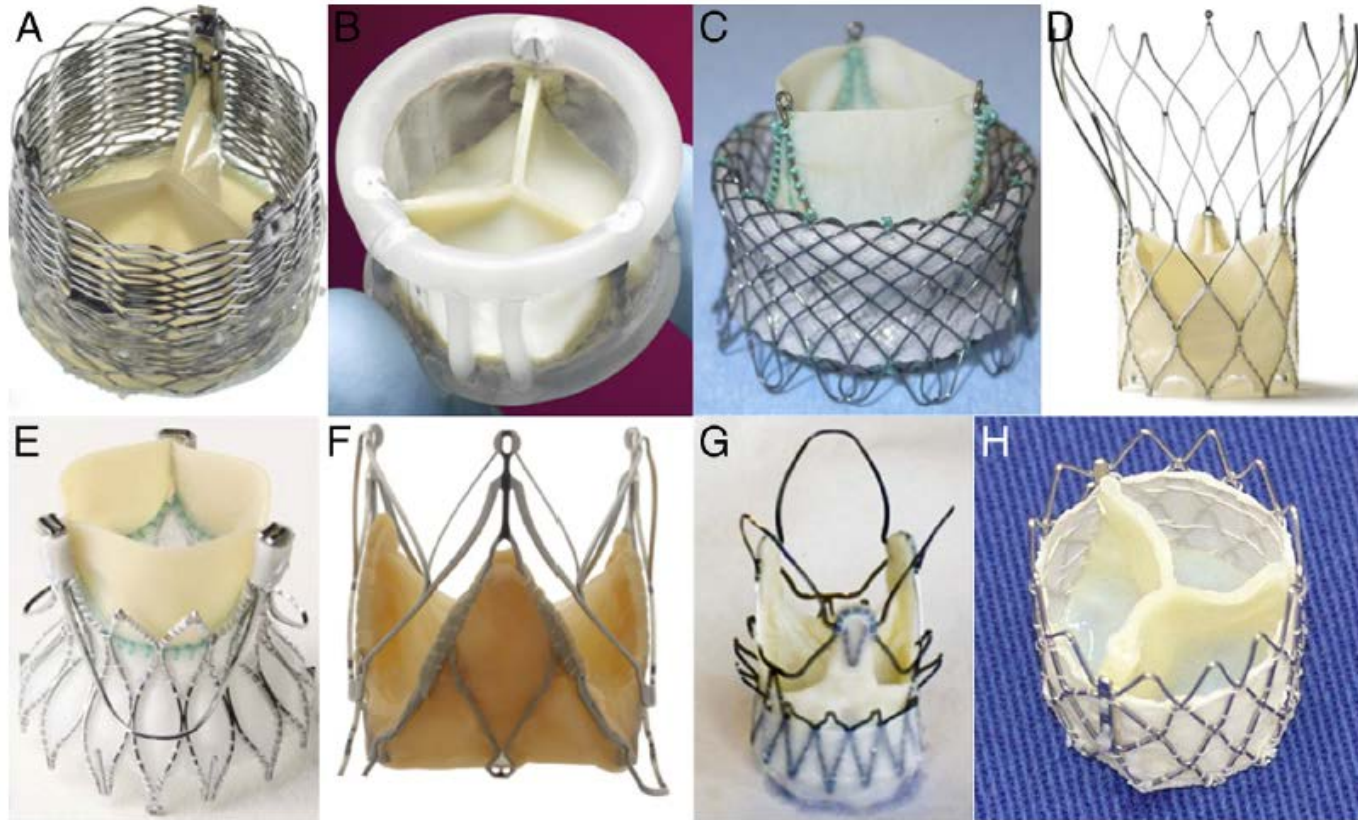


Figure 4 Valves Undergoing Early Evaluation

(A) Lotus (Boston Scientific Inc., Natick, Massachusetts), (B) Direct Flow (Direct Flow Medical Inc., Santa Rosa, California), (C) HLT (Bracco Inc., Princeton, New Jersey), (D) Portico (St. Jude Medical Inc., St. Paul, Minnesota), (E) Engager (Medtronic Inc., Minneapolis Minnesota), (F) JenaClip (JenaValve Inc., Munich, Germany), (G) Acurate valve (Symetis Inc., Ecublens, Switzerland), and (H) Inovare (Braille Biomedica Inc., São José do Rio Preto, Brazil) valves.

Valve Delivery Systems

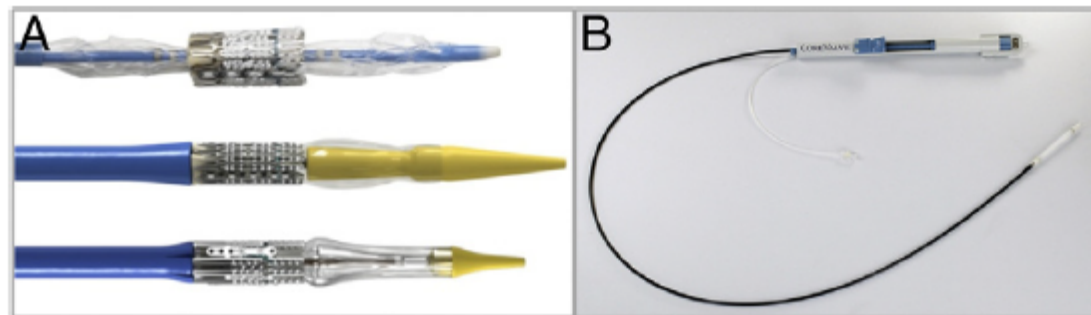


Figure 2 Valve Delivery Catheters

(A, top) The RetroFlex 1 delivery system for the Edwards SAPIEN THV (Edwards Lifesciences, Irvine, California) as used in the PARTNER 1 (Placement of AoRTic TraNscathetER Valve 1) trials (8 mm diameter). **(A, Middle)** The RetroFlex 3 system (Edwards Lifesciences). **(A, Bottom)** The NovaFlex/SAPIEN XT system (6 mm diameter; Edwards Lifesciences). **(B)** The Accutrak delivery system with the Medtronic CoreValve (6 mm diameter, also with a tapered nosecone; Medtronic, Minneapolis, Minnesota). The prosthesis is enclosed within an outer sheath.

Preclose technique

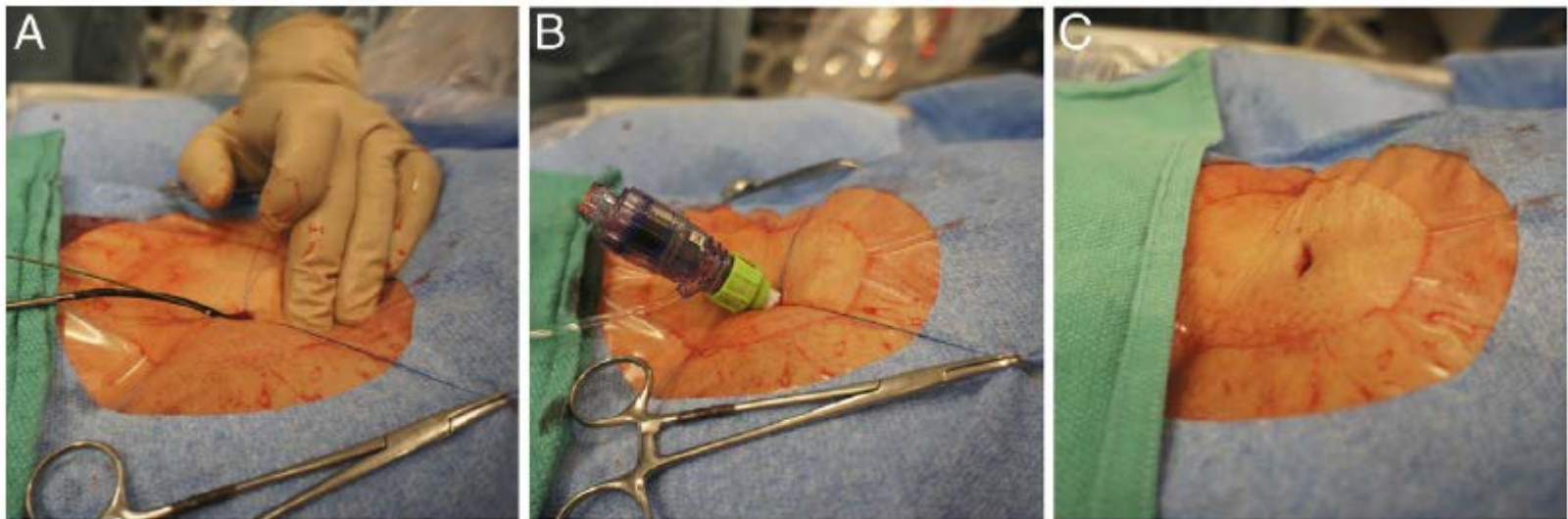
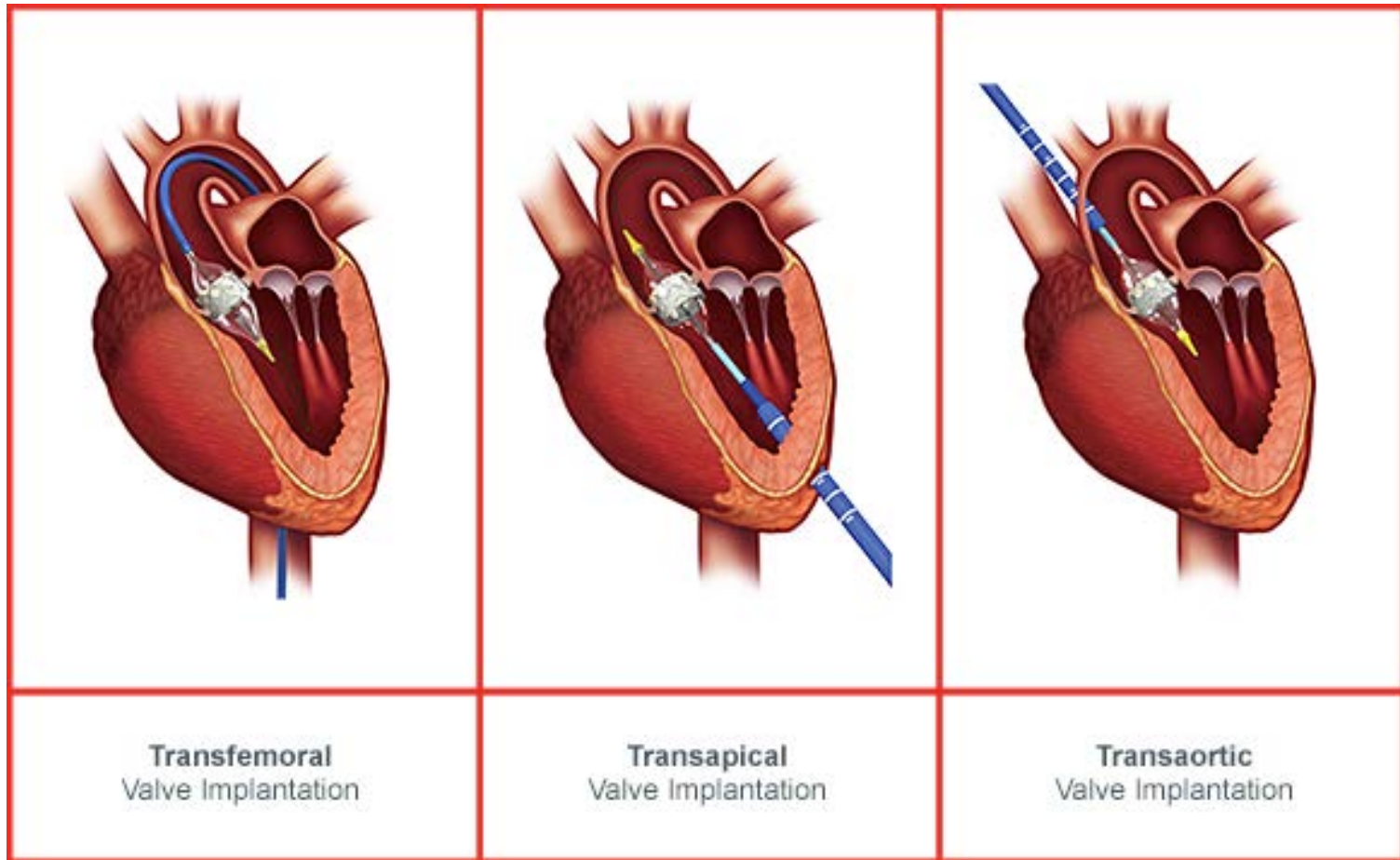


Figure 5 Percutaneous Access and Closure

(A) The femoral artery is punctured and a guidewire placed within the artery. Percutaneous sutures are placed using a "pre-closure" device. (B) The large vascular access sheath is inserted. (C) Following sheath removal the sutures are tightened.

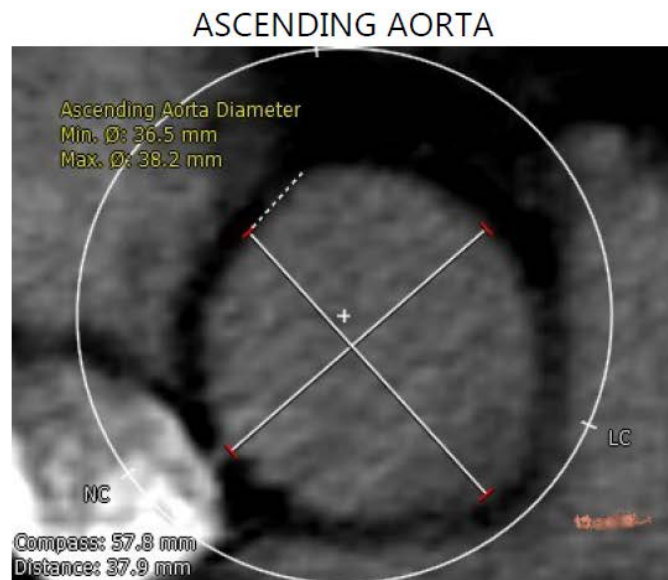
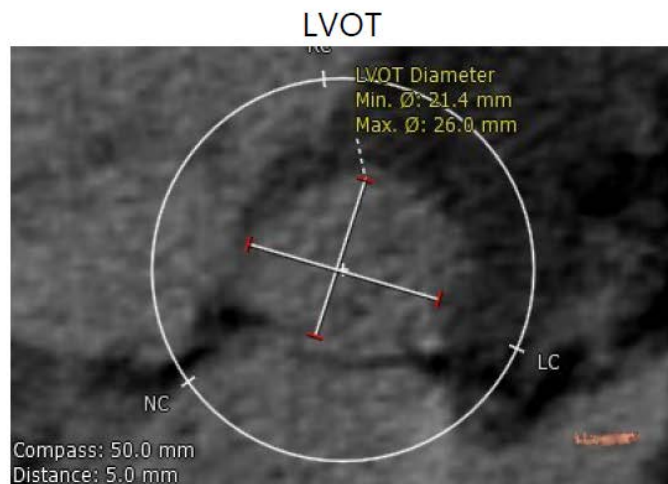
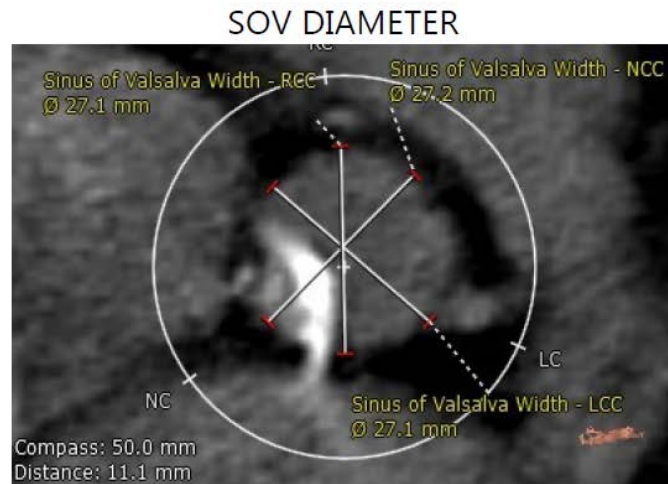
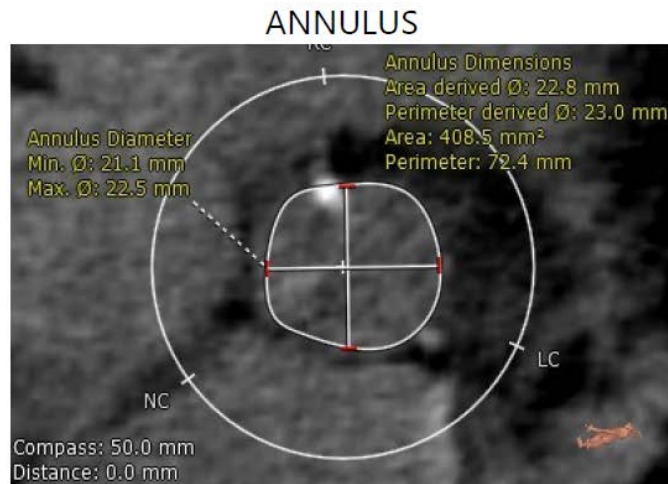
TAVI Route



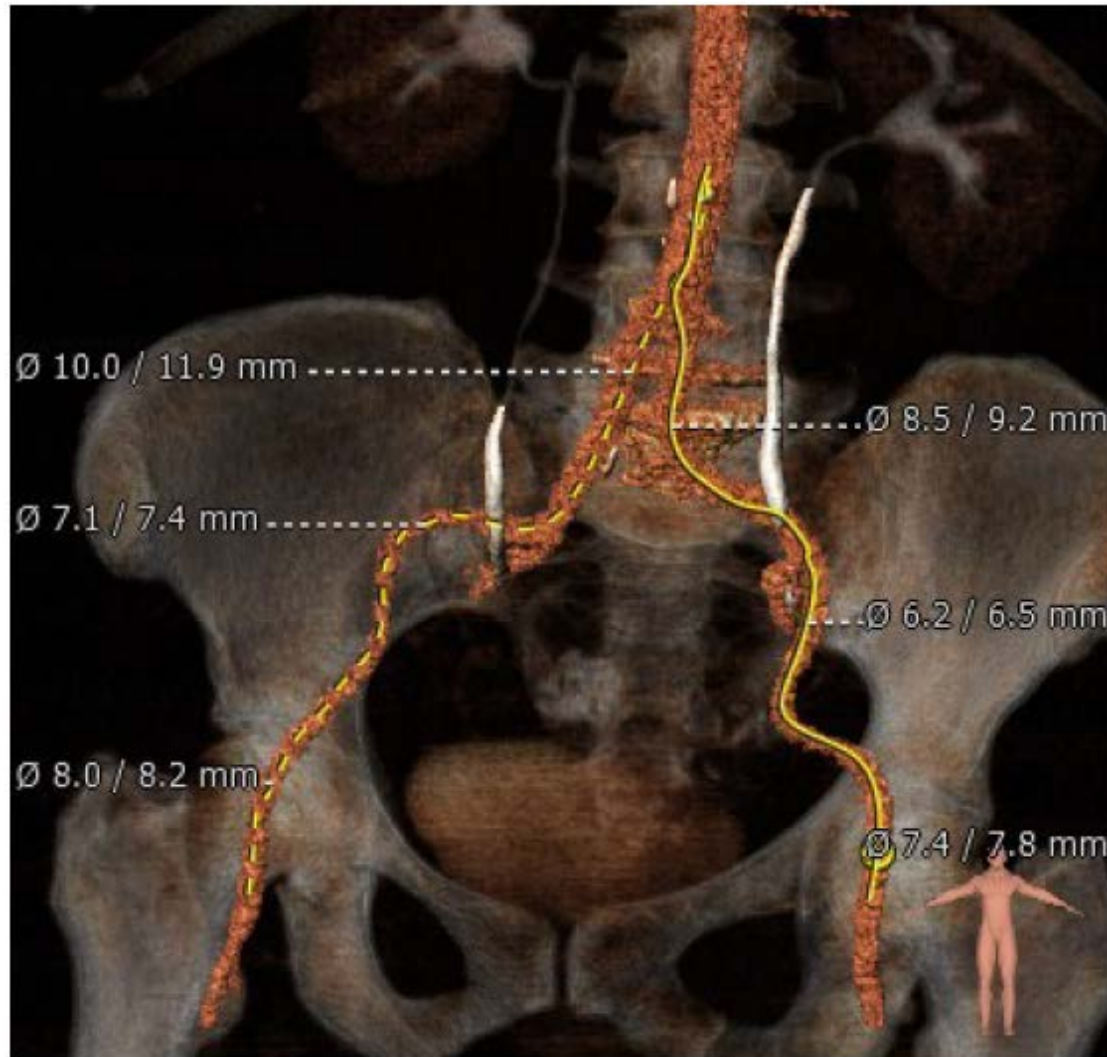
TAVI Screening

- Euroscore > 20%
- Euroscore II > 7%
- STS Score > 8%
- Echocardiogram
- Coronary Angiography
- CT Angiography (Aorta & Peripherals)

CT Angiography (LVOT-Annulus-SOV-Aorta)



CT Angiography (Peripherals)



Screening Report

Max Ascending Aorta Diameter (mm)

38.2

Sinotubular Junction Diameter (mm)

29.6

x

30.0

Min

Max

ANNULUS

Diameter (mm)

21.1

22.5

x

21.8 mm

Min

Max

Mean

Perimeter (mm)

72.4

x

23.0

Derived
Diameter

Area

408.5

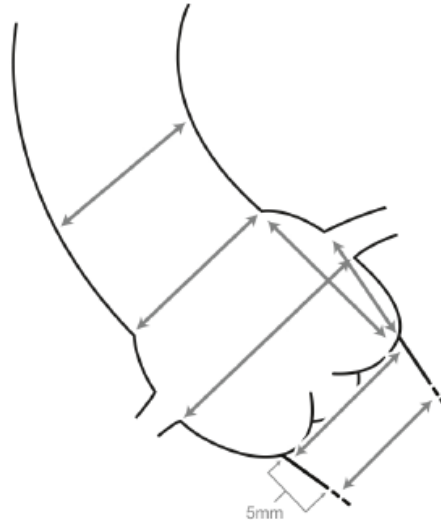
mm²

,

22.8

mm

Derived
Diameter



Sinus of Valsalva Diameter (mm)

27.1

27.1

27.2

LCC

RCC

NCC

Sinus of Valsalva Height (mm)

17.7

20.0

19.3

LCC

RCC

NCC

Coronary Ostia Height (mm)

10.4

13.2

Left

Right

LVOT Diameter (mm)

21.4

x

26.0

Min

Max

RIGHT

CIA Min Diameter (mm)

10.0

x

11.9

EIA Min Diameter (mm)

7.1

x

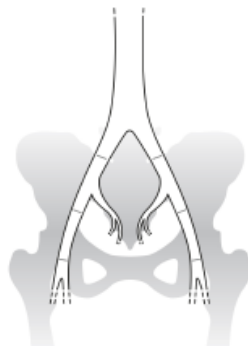7.4

Femoral Min Diameter (mm)

8.0

x

8.2



LEFT

CIA Min Diameter (mm)

8.5

x

9.2

EIA Min Diameter (mm)

6.2

x

6.5

Femoral Min Diameter (mm)

7.4

x

7.8

RIGHT

Subclavian Min
Diameter (mm)

x

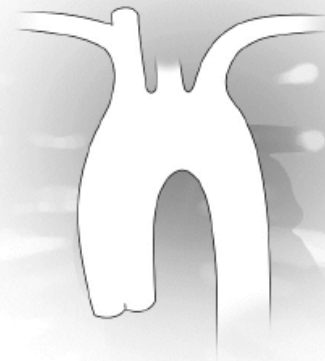Annular Angulation

LEFT

Subclavian Min
Diameter (mm)

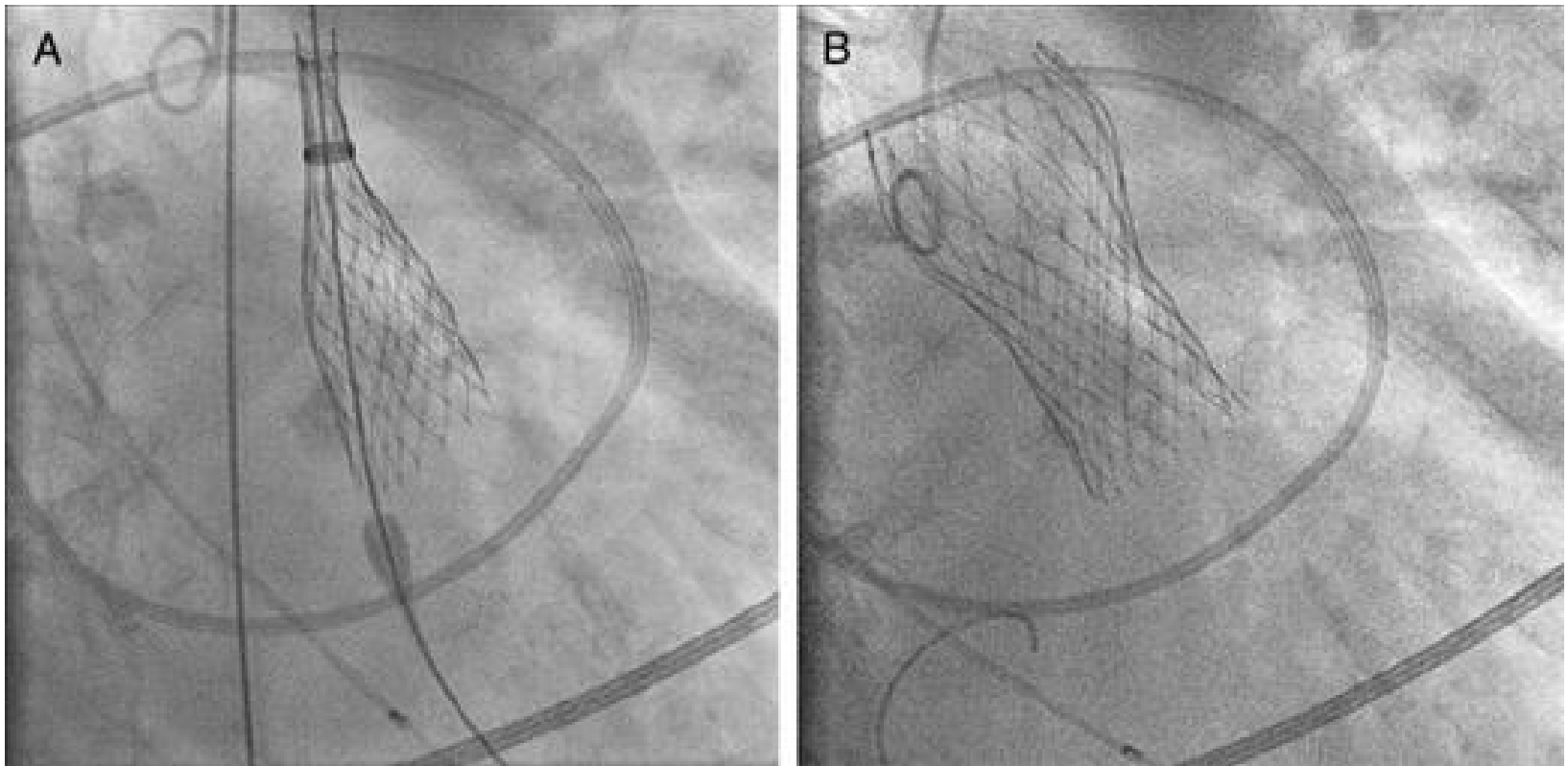
x

Please review
imaged for direct
aortic evaluation.

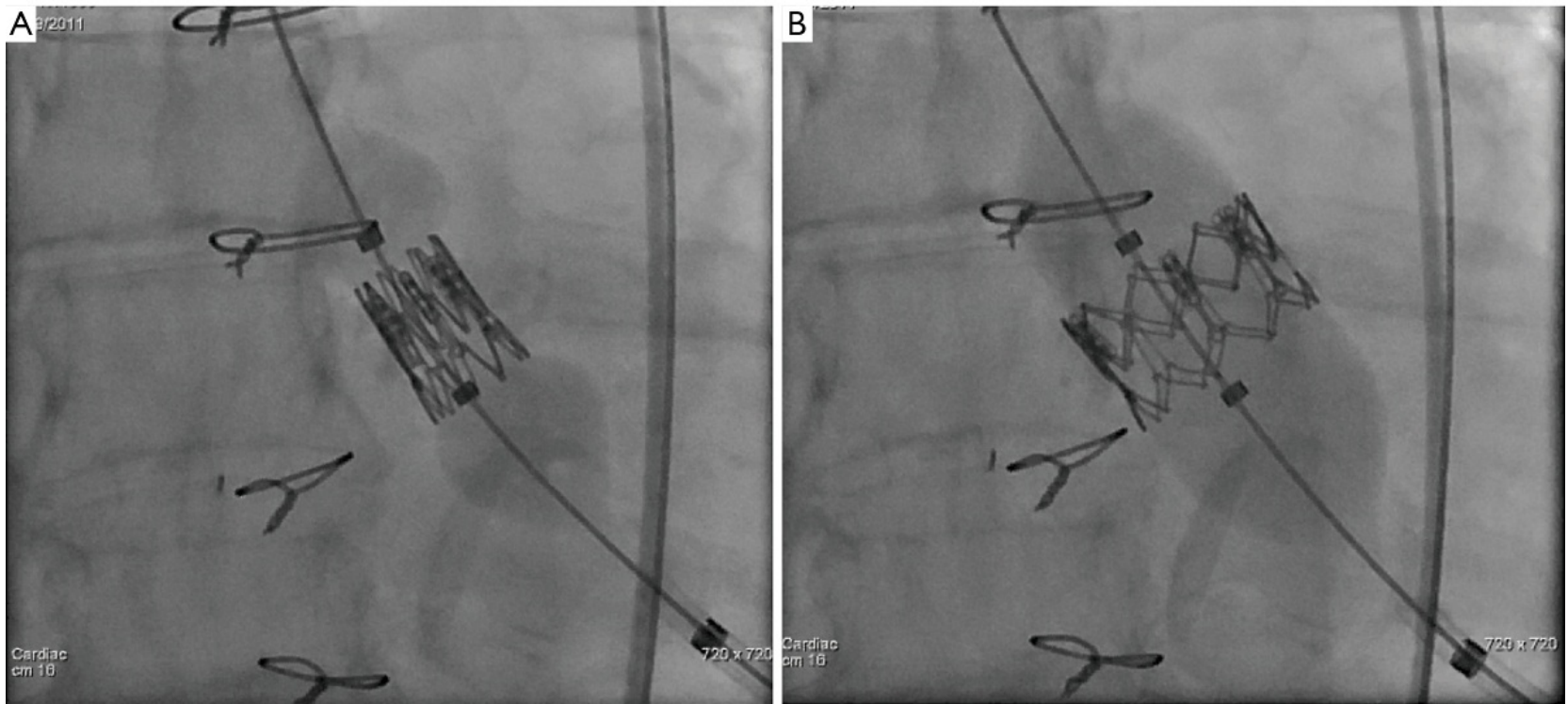


Calcium: Mild ☒ Moderate ☐ Severe ☐

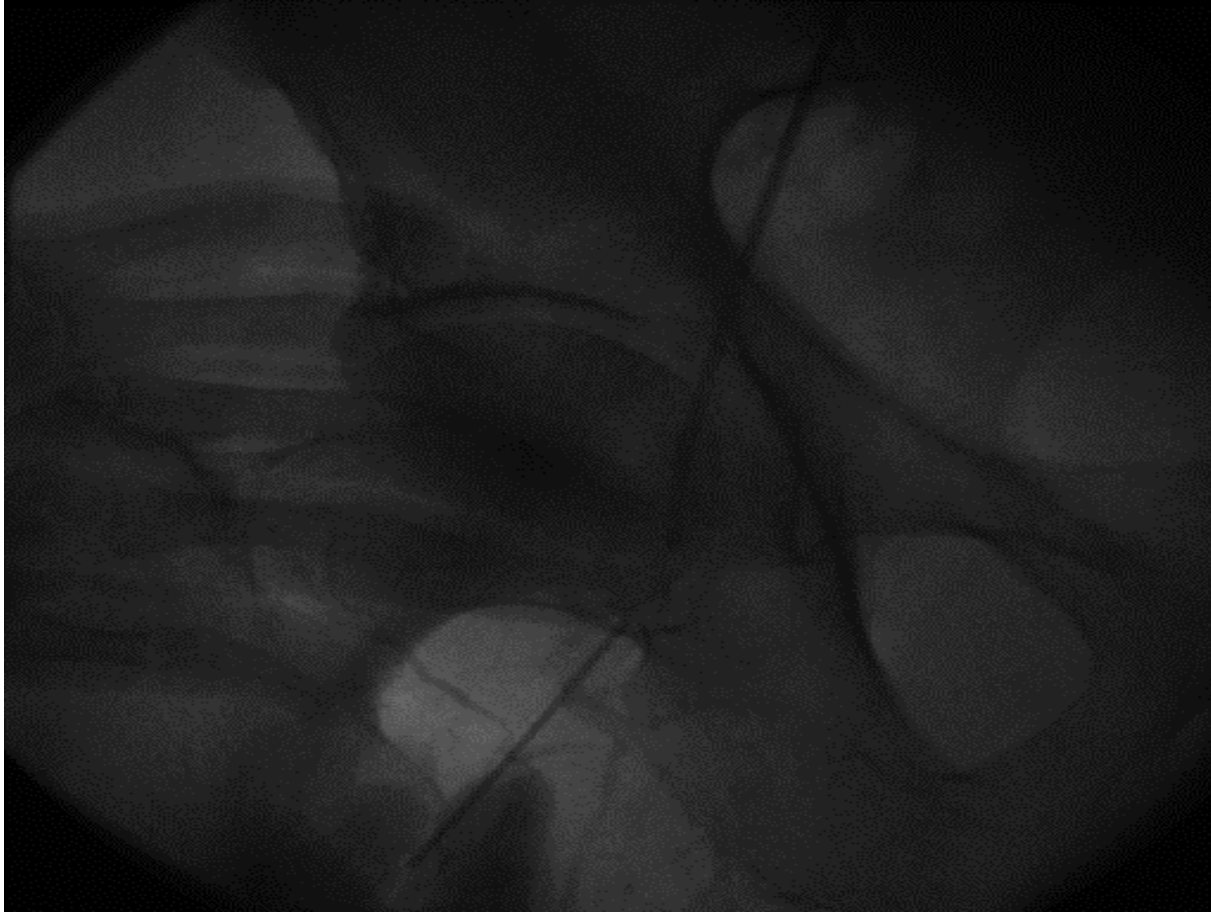
Fluoroscopic Image of Valve Release (CoreValve)



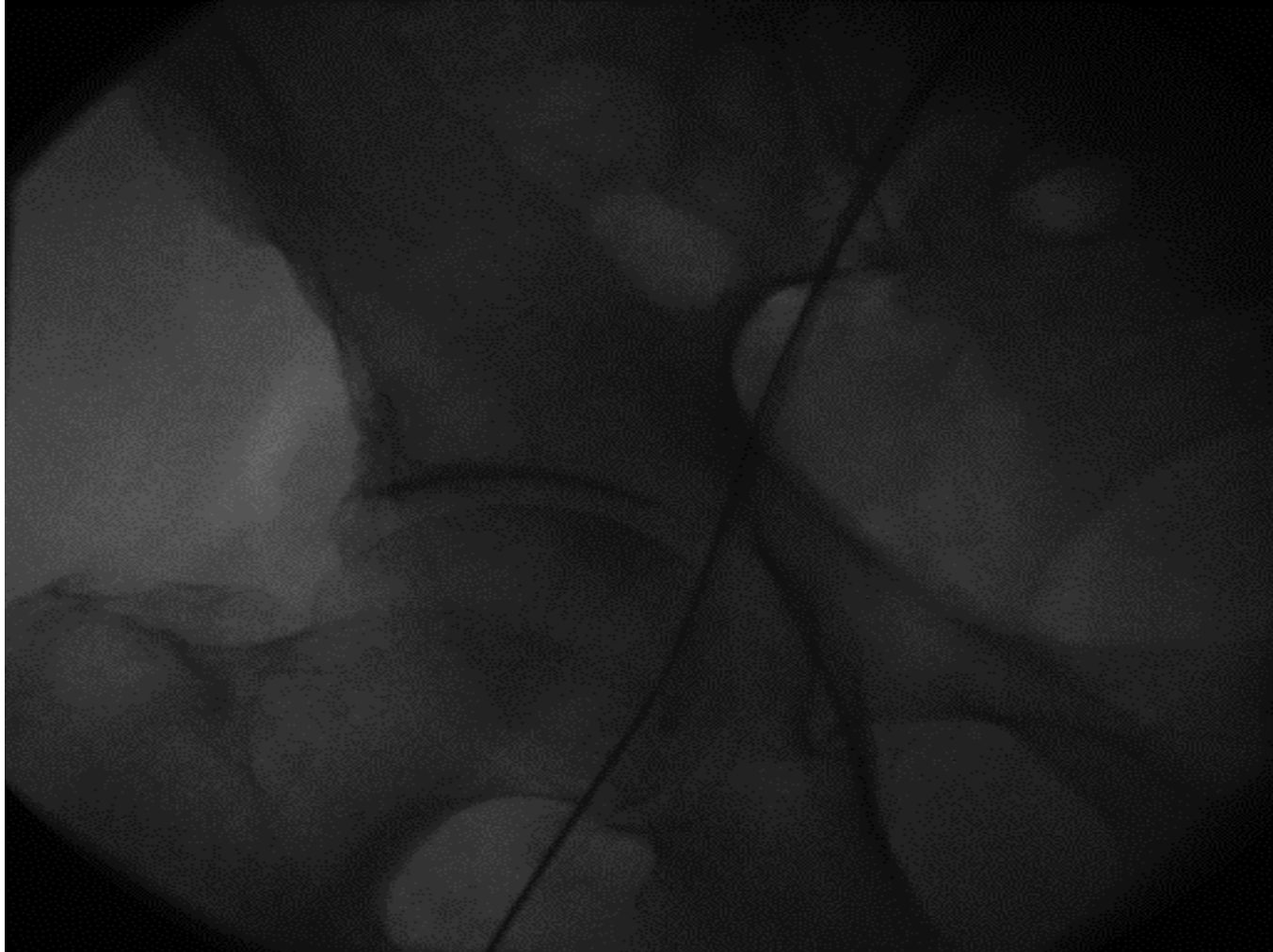
Fluoroscopic Image of Valve Release (Edwards-Sapien)



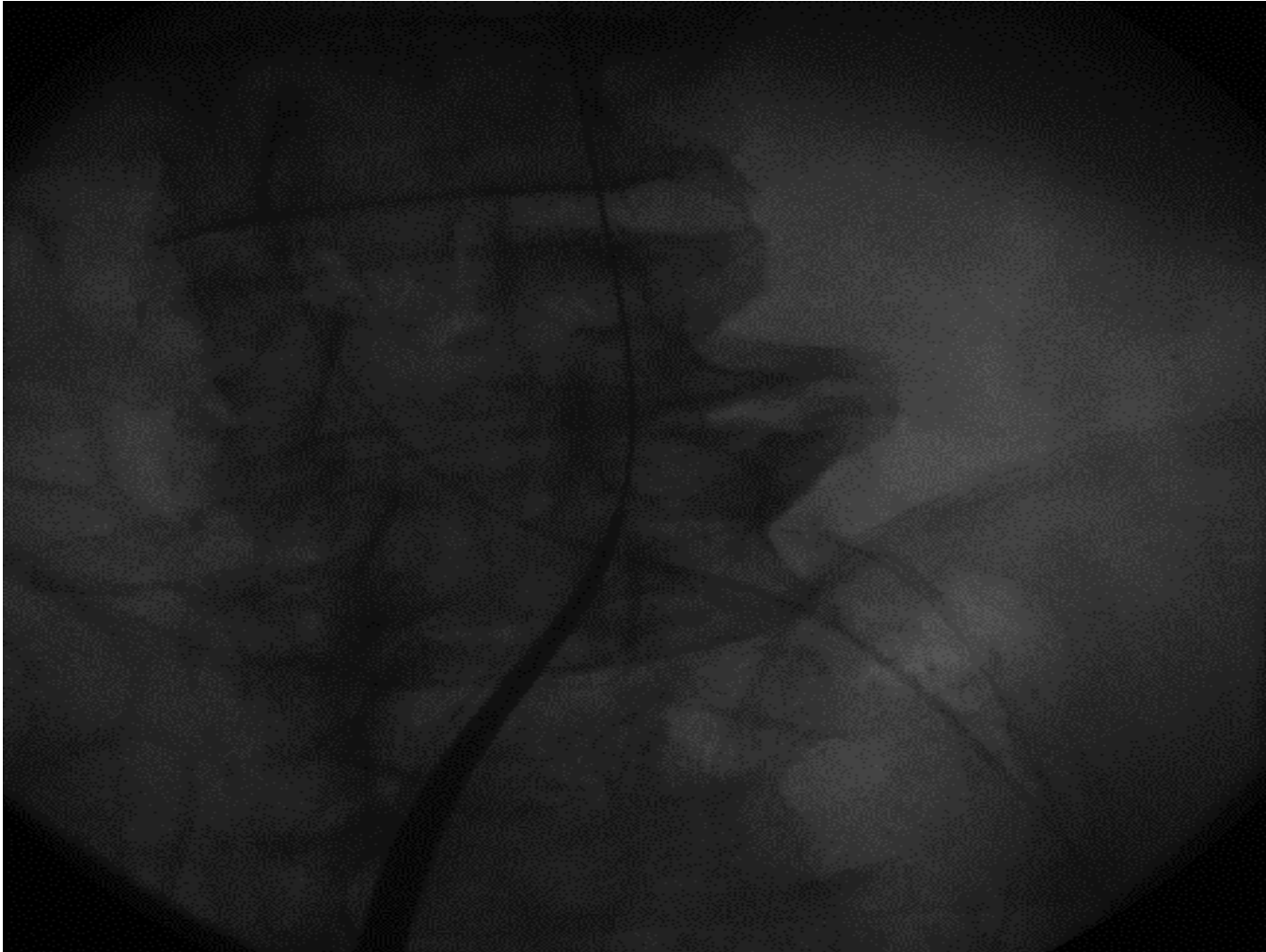
Femoral Arterial Puncture (1)



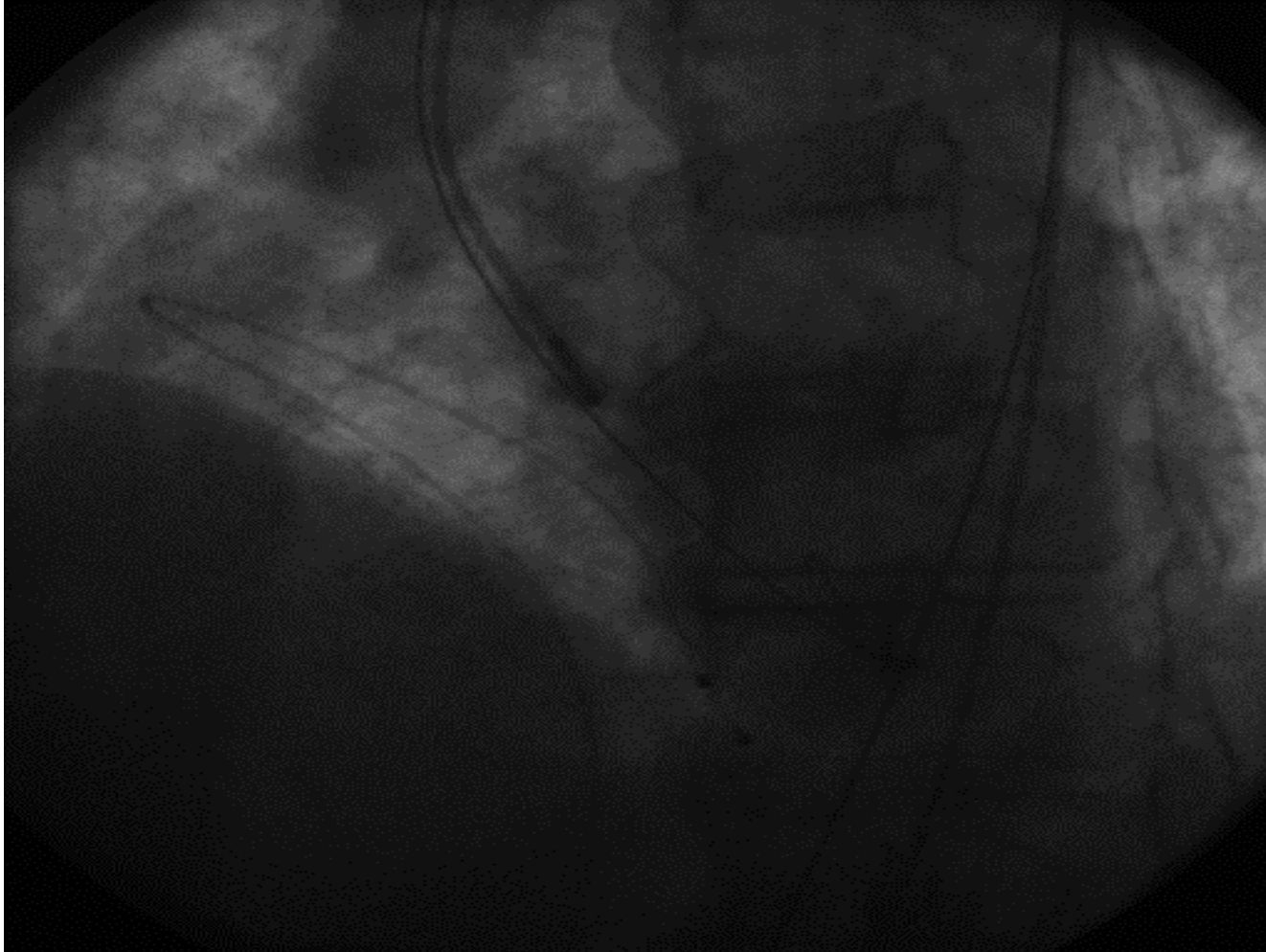
Femoral Arterial Puncture (2)



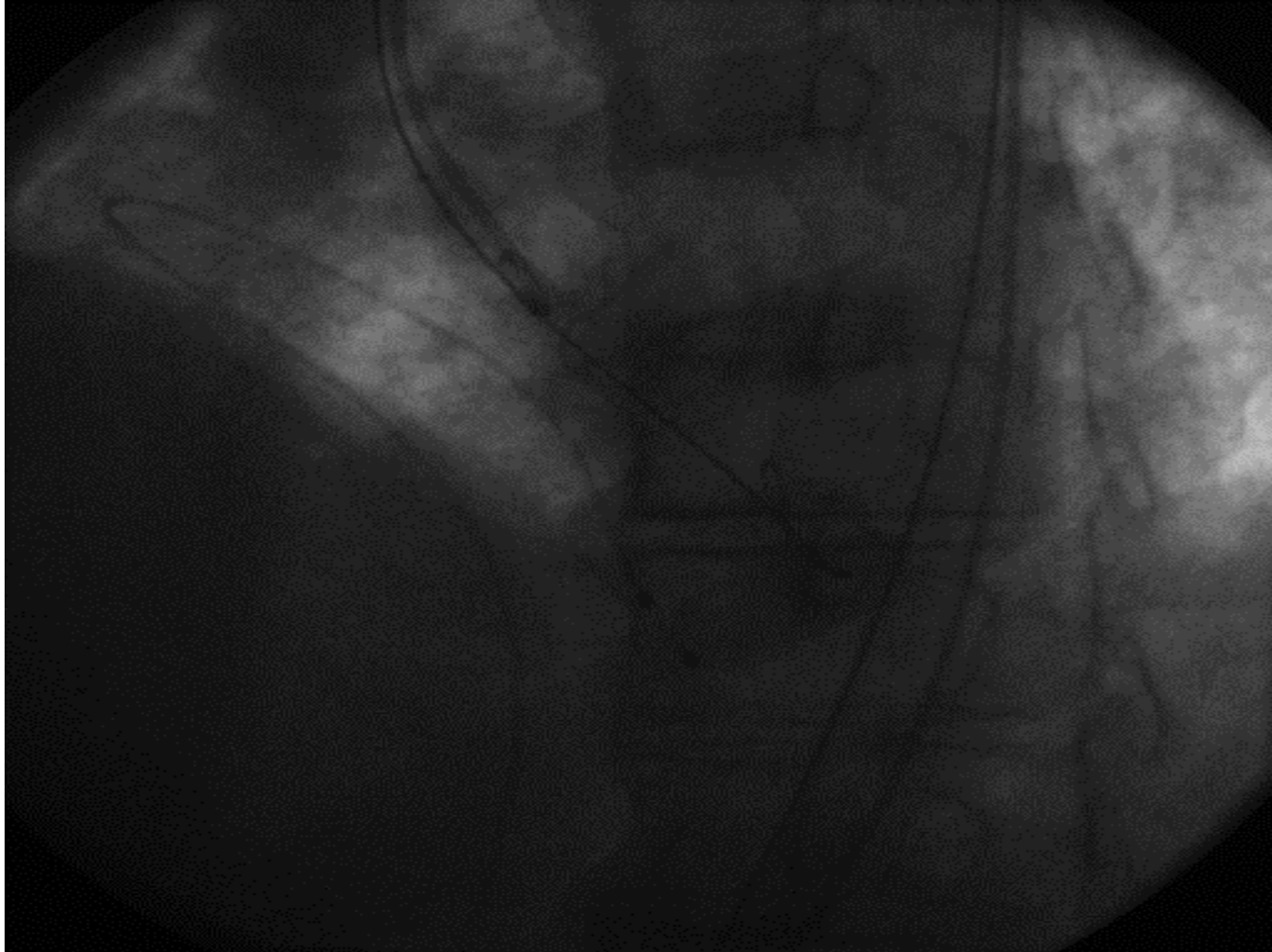
Sheath Insertion (3) (14-22 F)



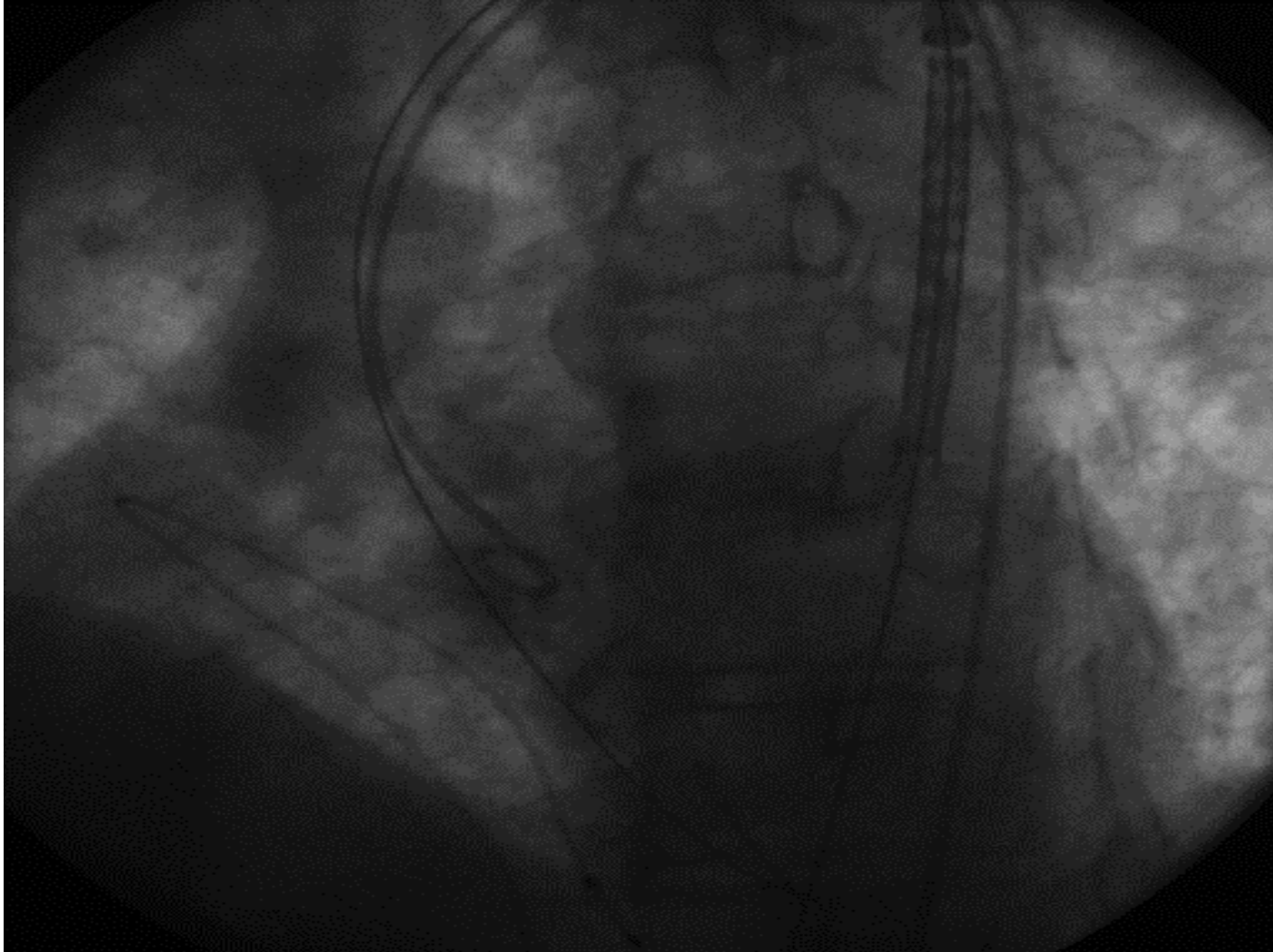
Baseline Aortography (4)



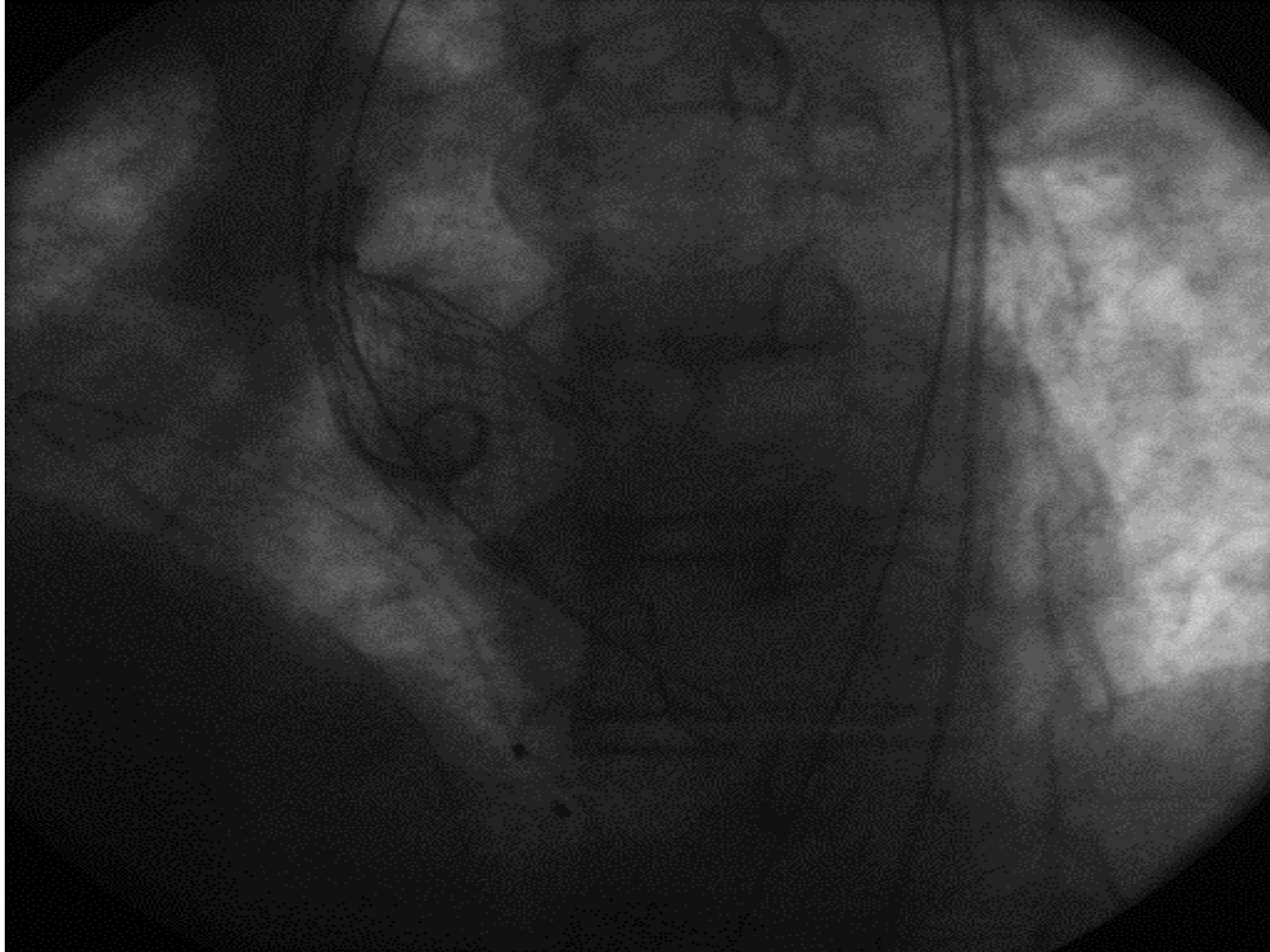
Aortic Valvuloplasty (5)



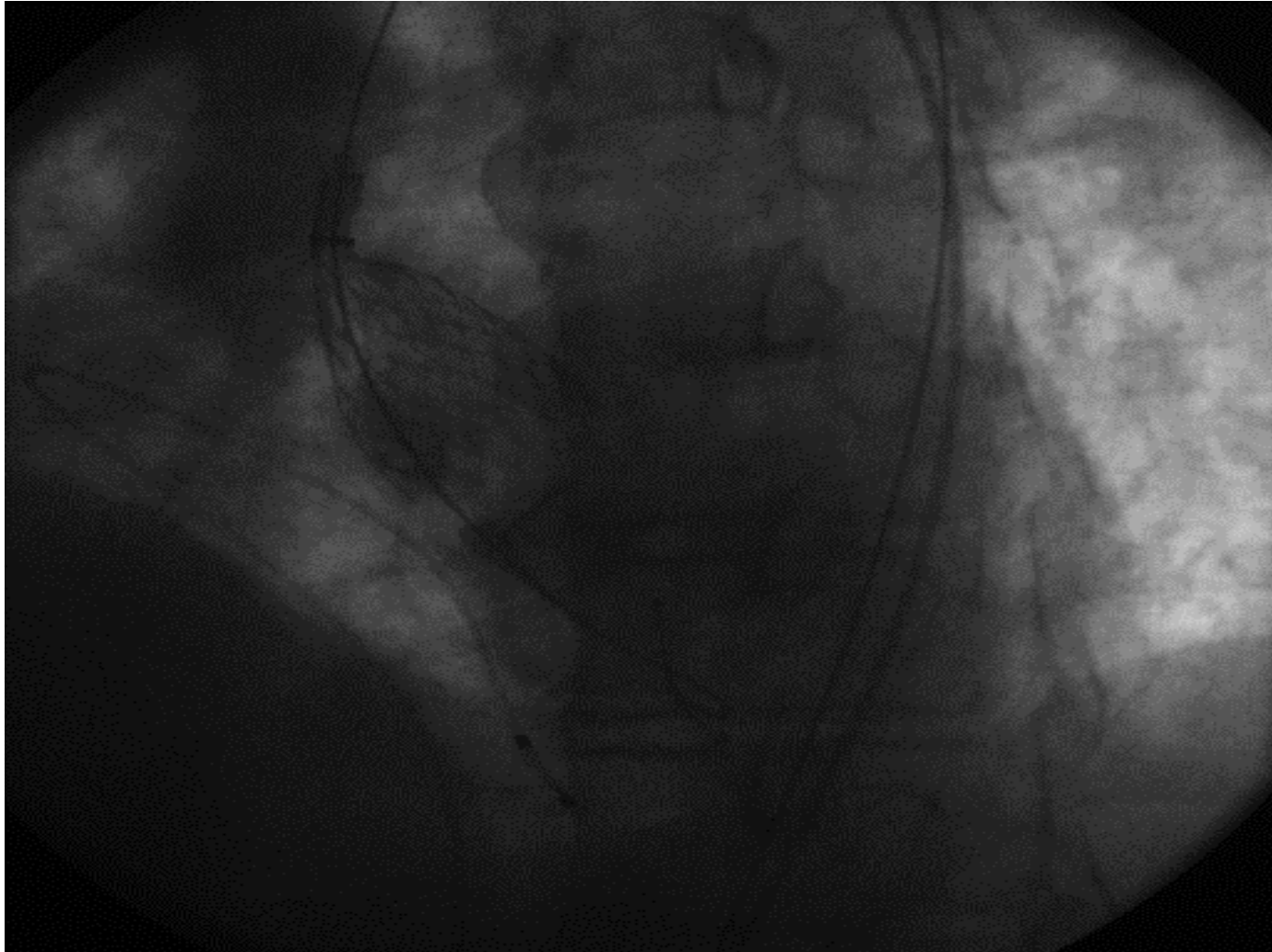
Valve Delivery System (6)



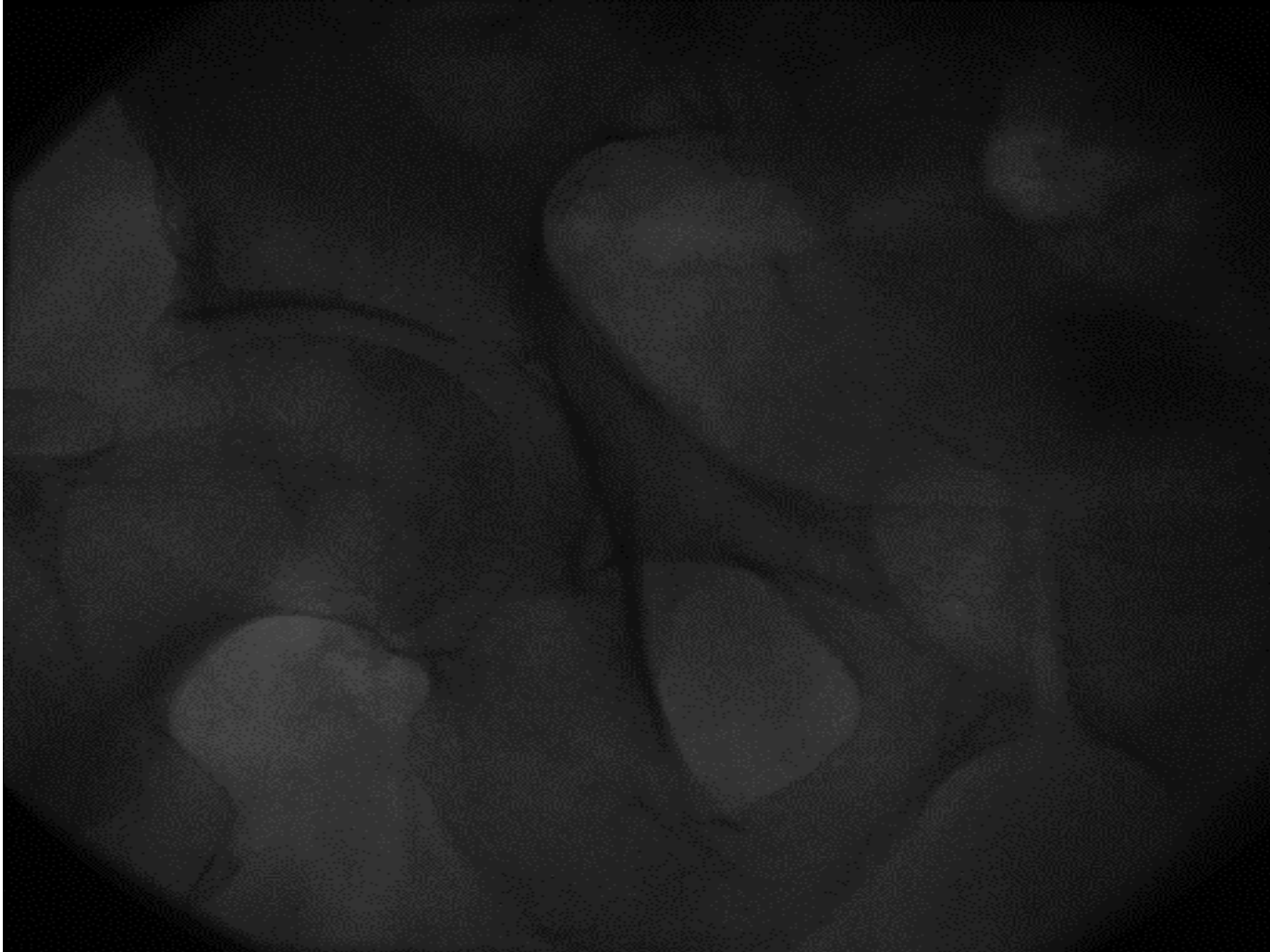Initial Valve Release (CoreValve) (7)



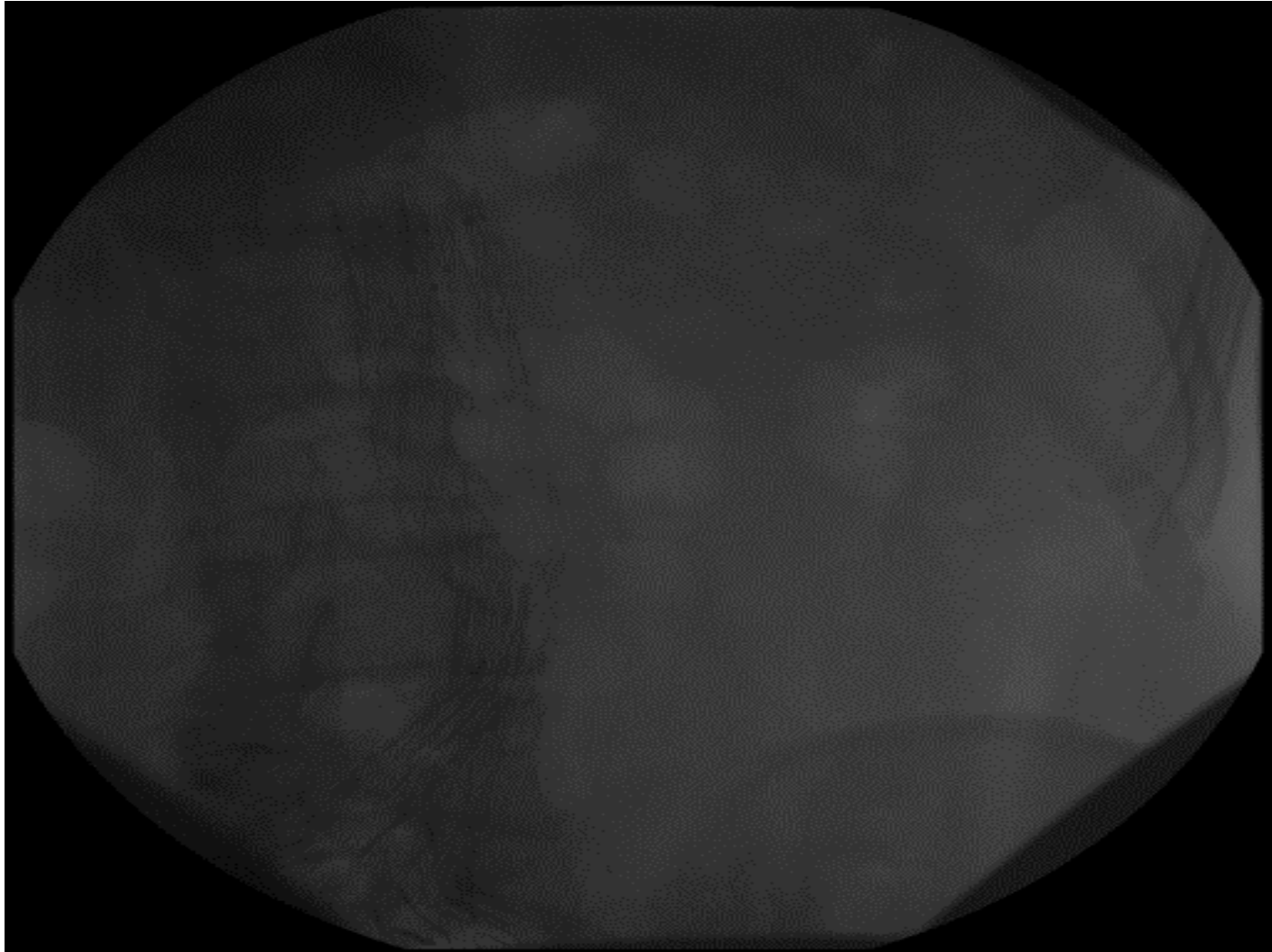
Final Valve Release (CoreValve) (8)



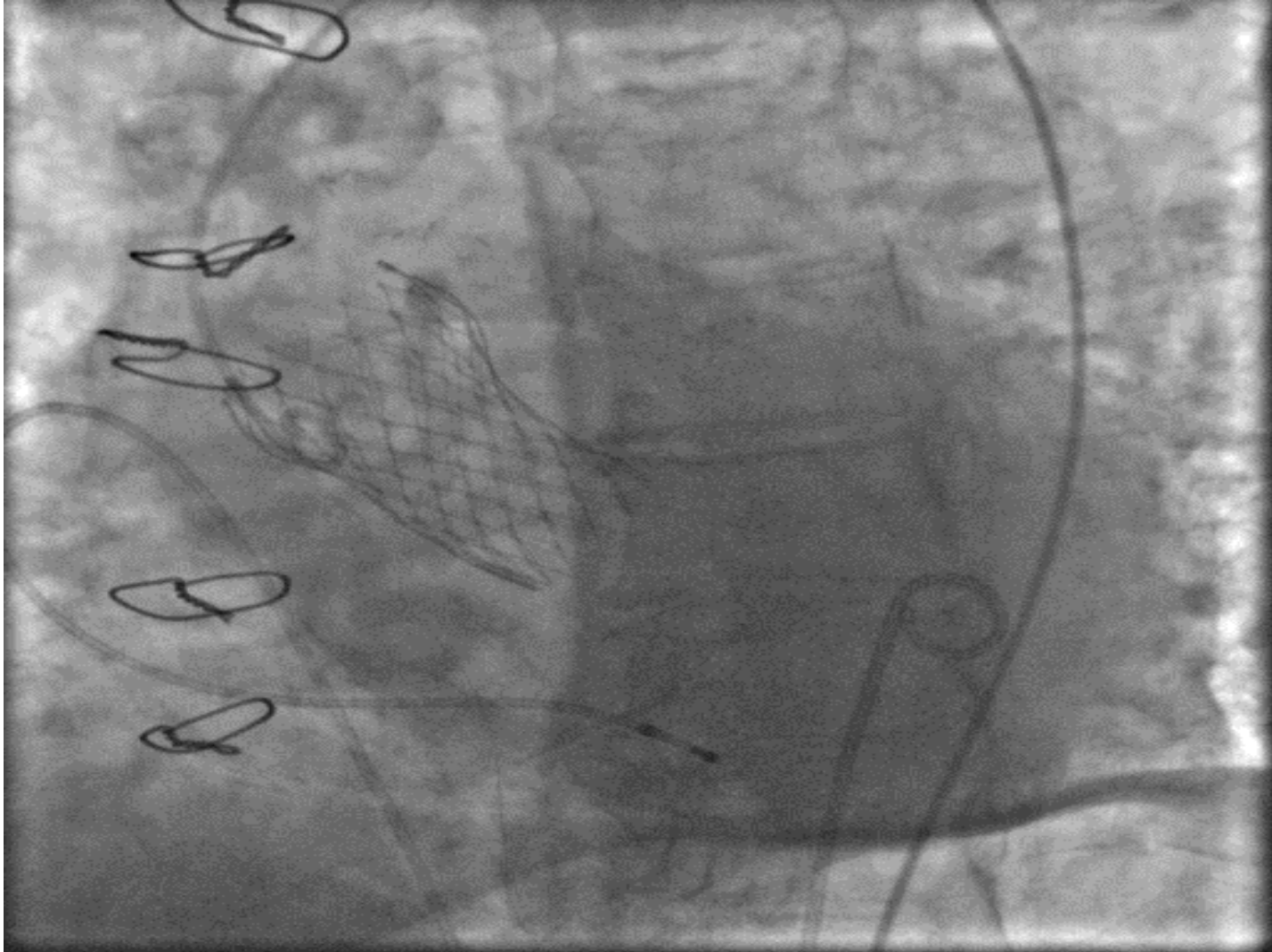
Femoral Angiography after closure (9)



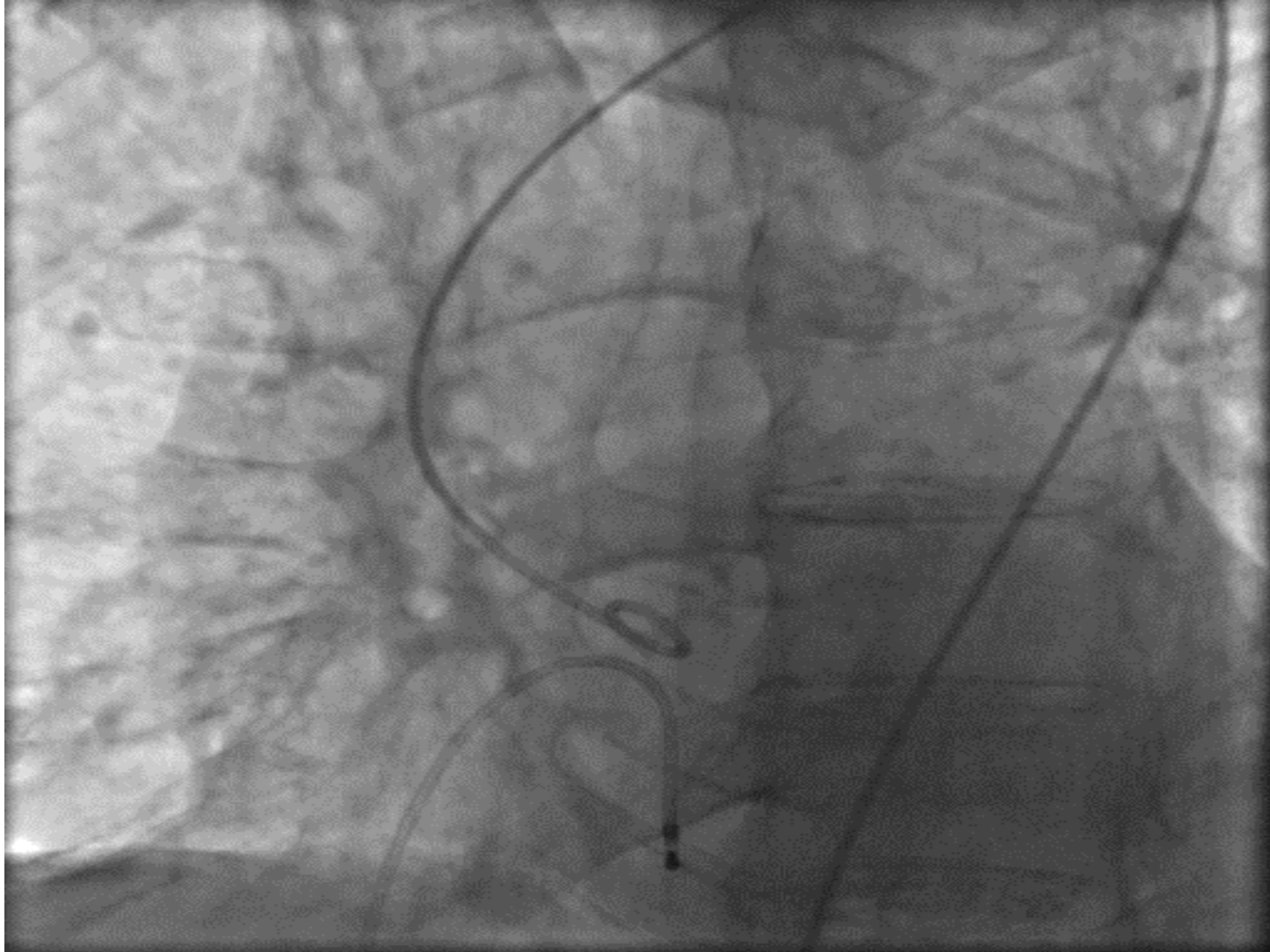TAVI through Aortic Stent (10)



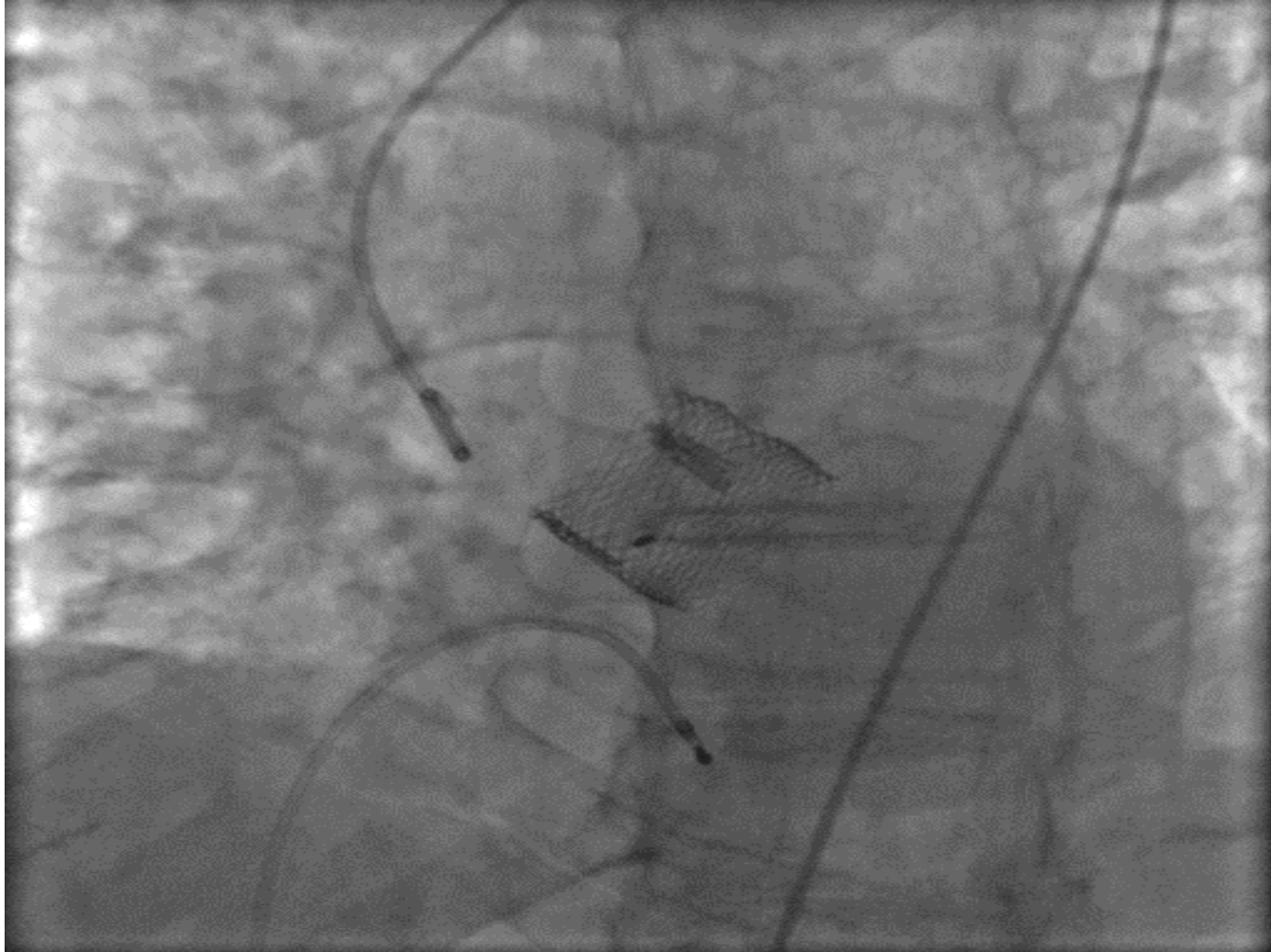
Final Evolut R Placement (11)



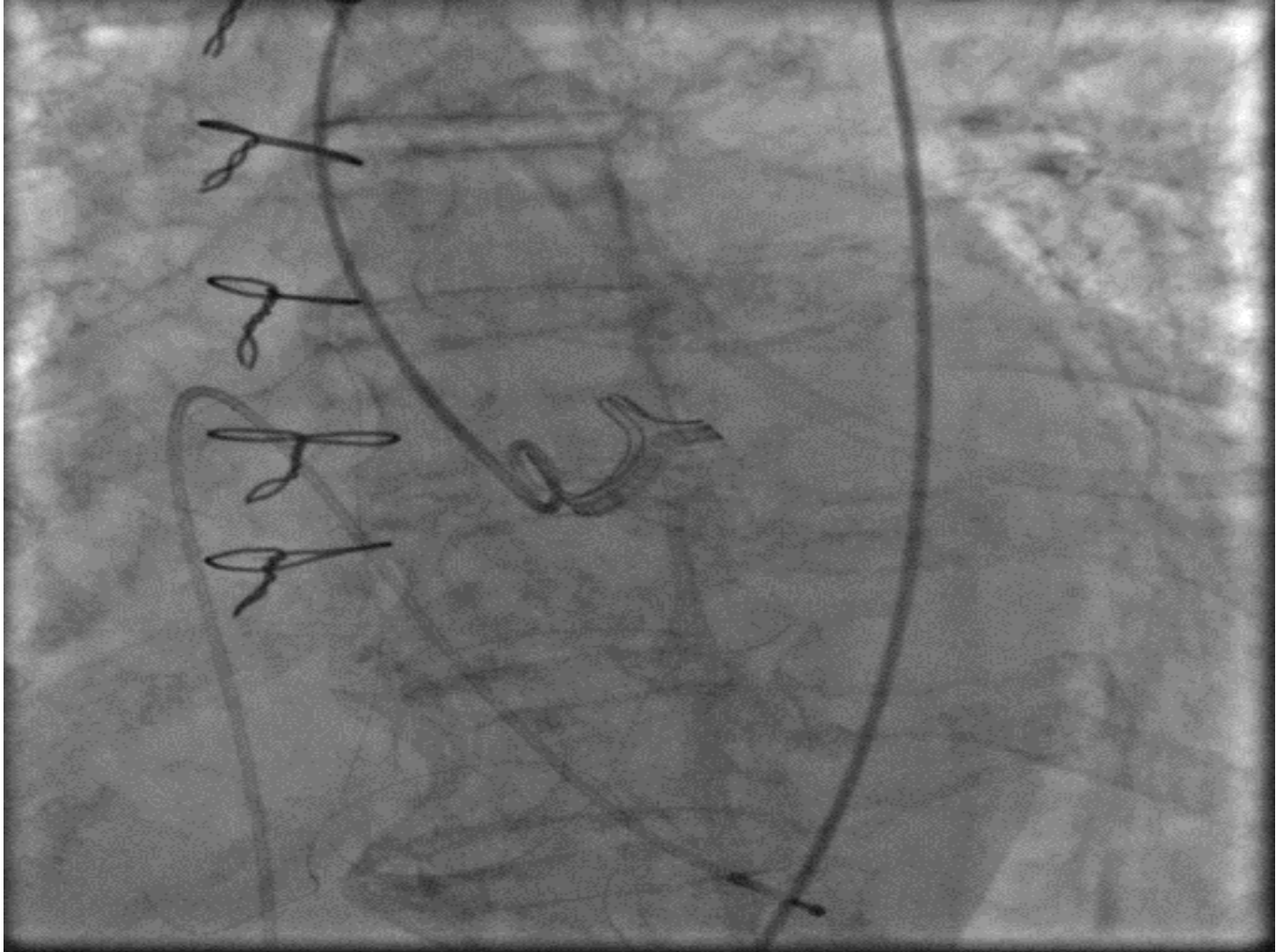AS - Lotus Valve – Aortography (12)



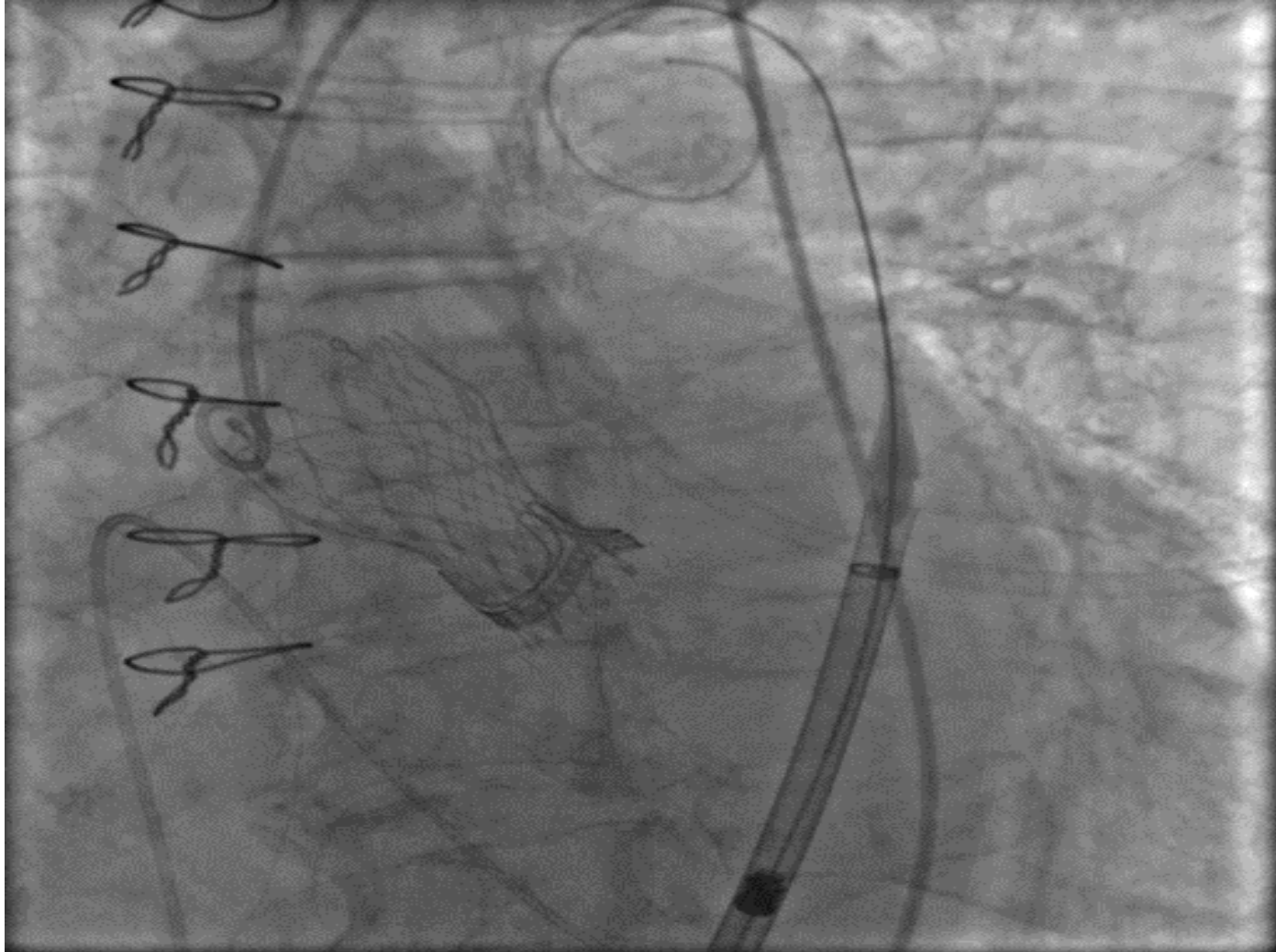
Final Placement of Lotus Valve (13)



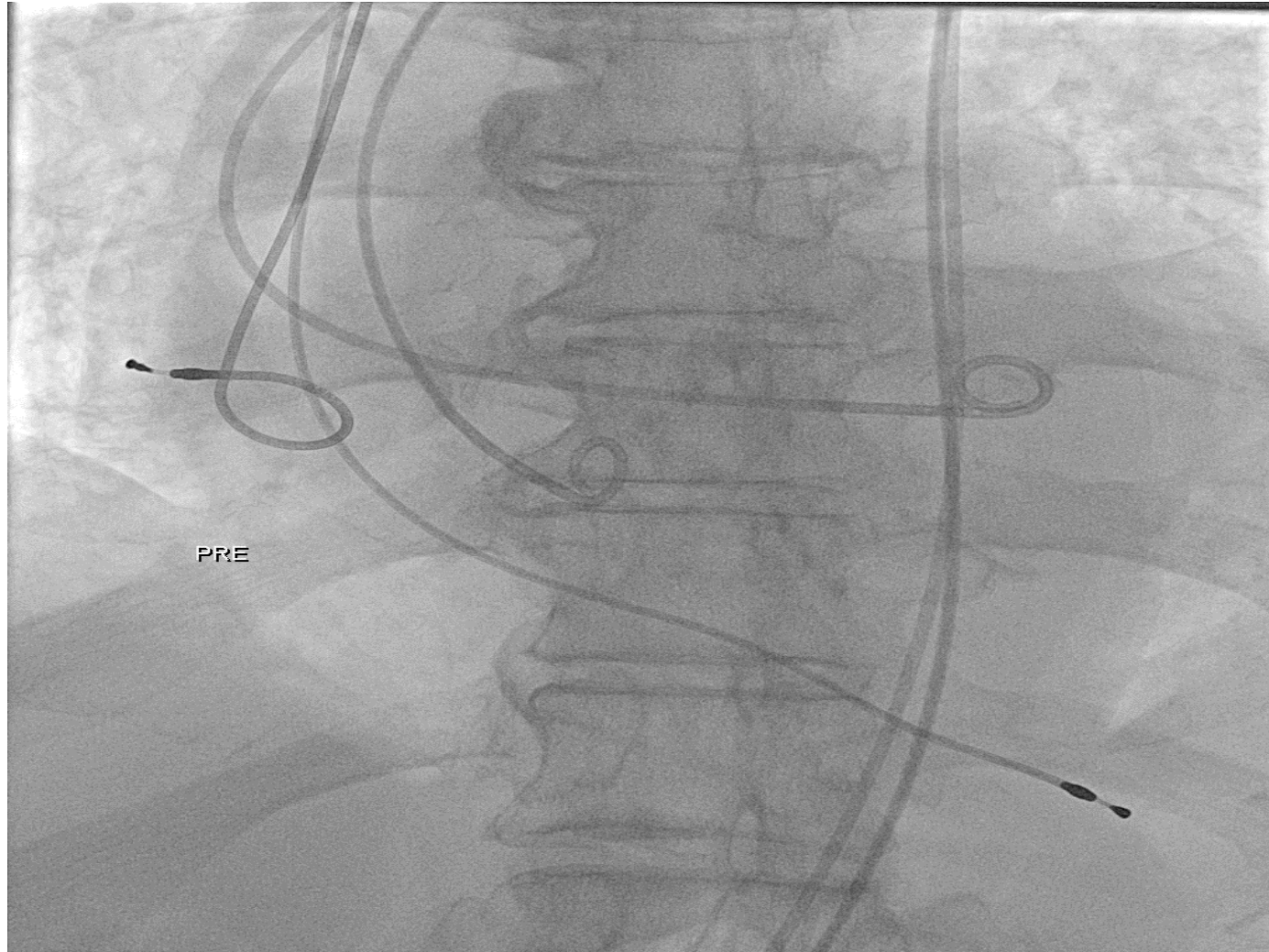
Valve in Valve CE Magna 21(14)




Valve in Valve Evolut R (15)




TAVI in Bicuspid AV (23)




Sizing in Bicuspid AV (24)



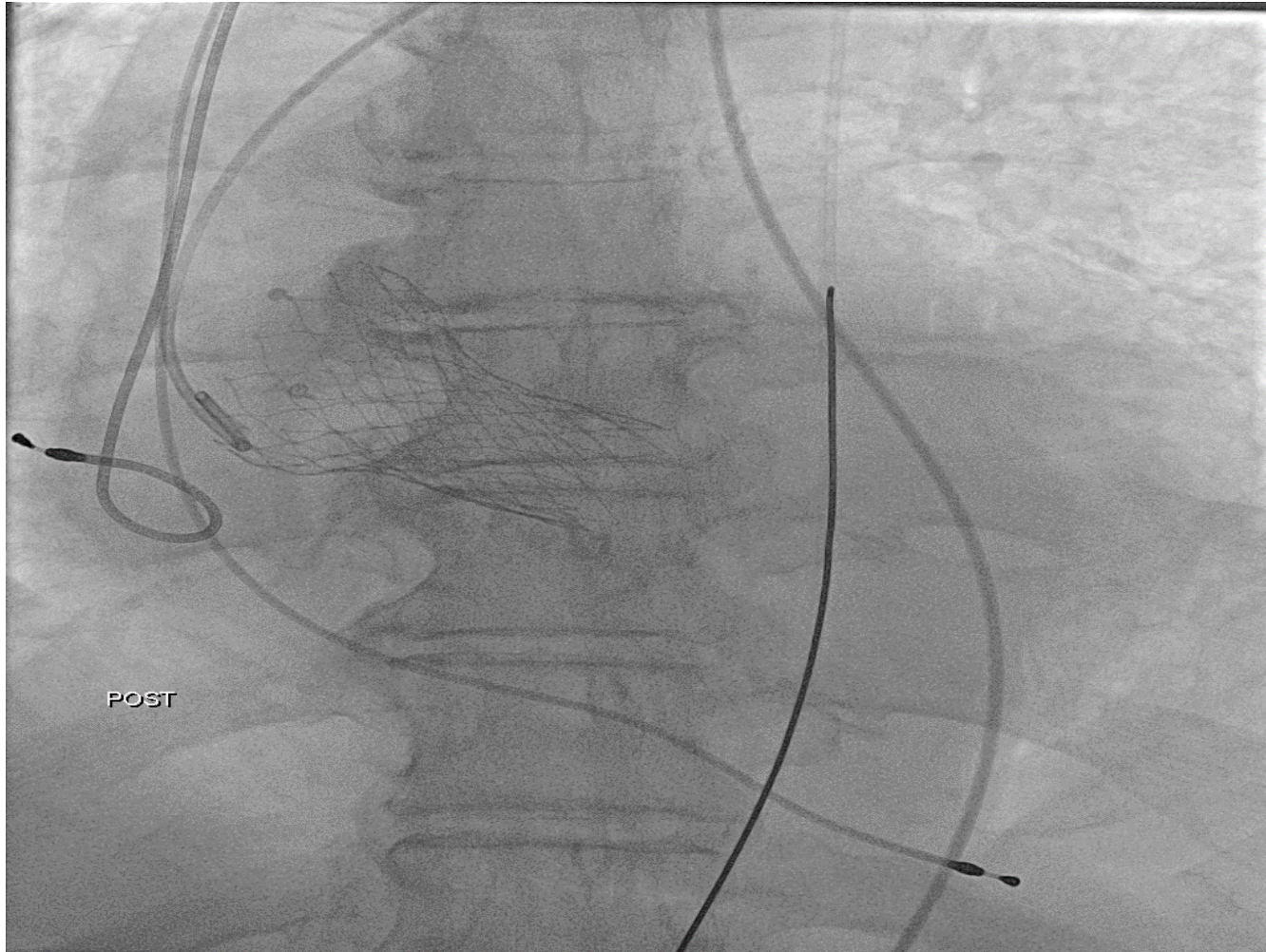
Initial Result (25)



Balloon expansion (26)



Final Result (27)



TAVI Vascular Arterial Complications

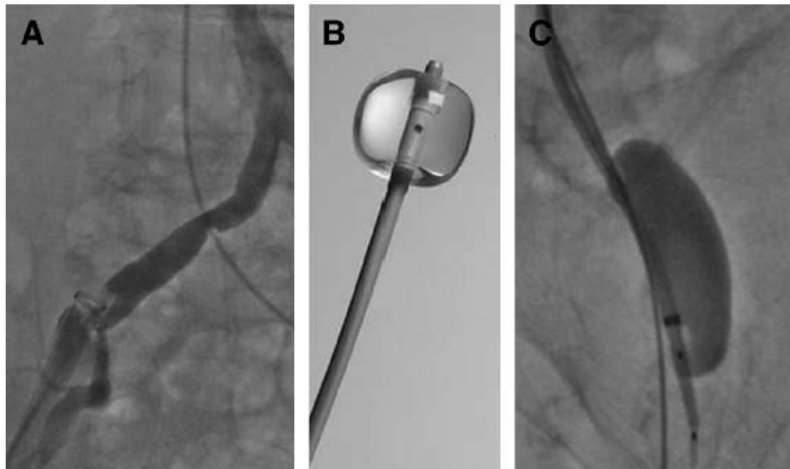


Figure 1. Vascular Injury

(A) Dissection of the right iliac artery. (B) Occlusion balloon (Occlusion Catheter, Boston Scientific, Natick, Massachusetts). (C) Occlusion balloon (Coda Occlusion Balloon Catheter, Cook Medical, Inc., Bloomington, Indiana) inflated in the left iliac artery.

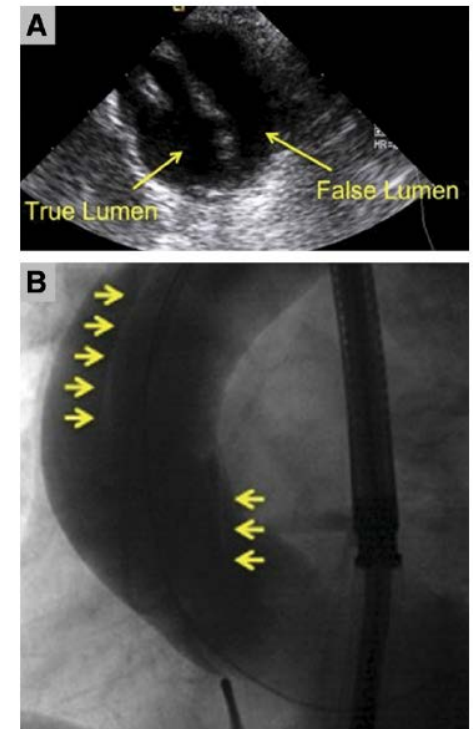
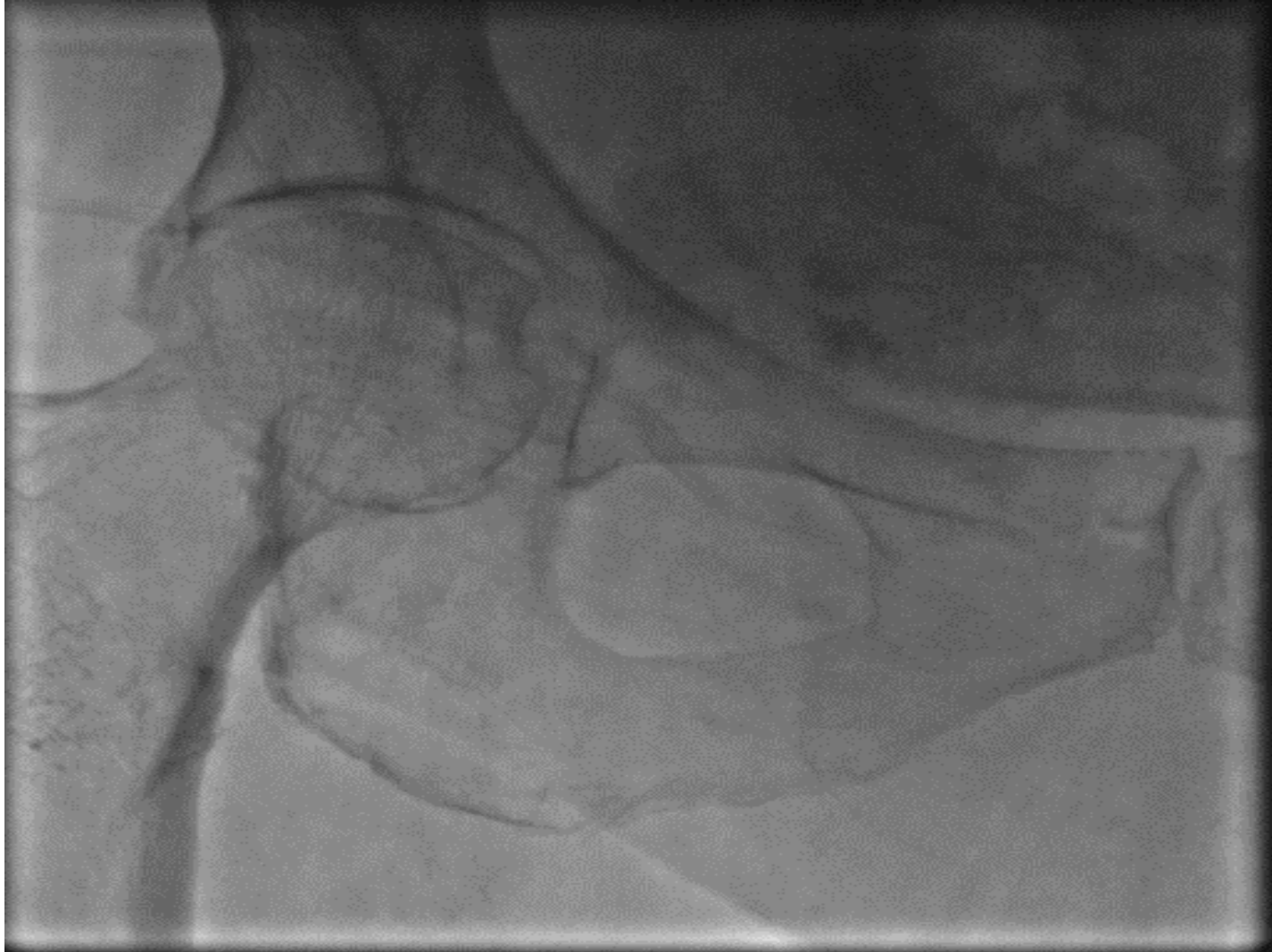

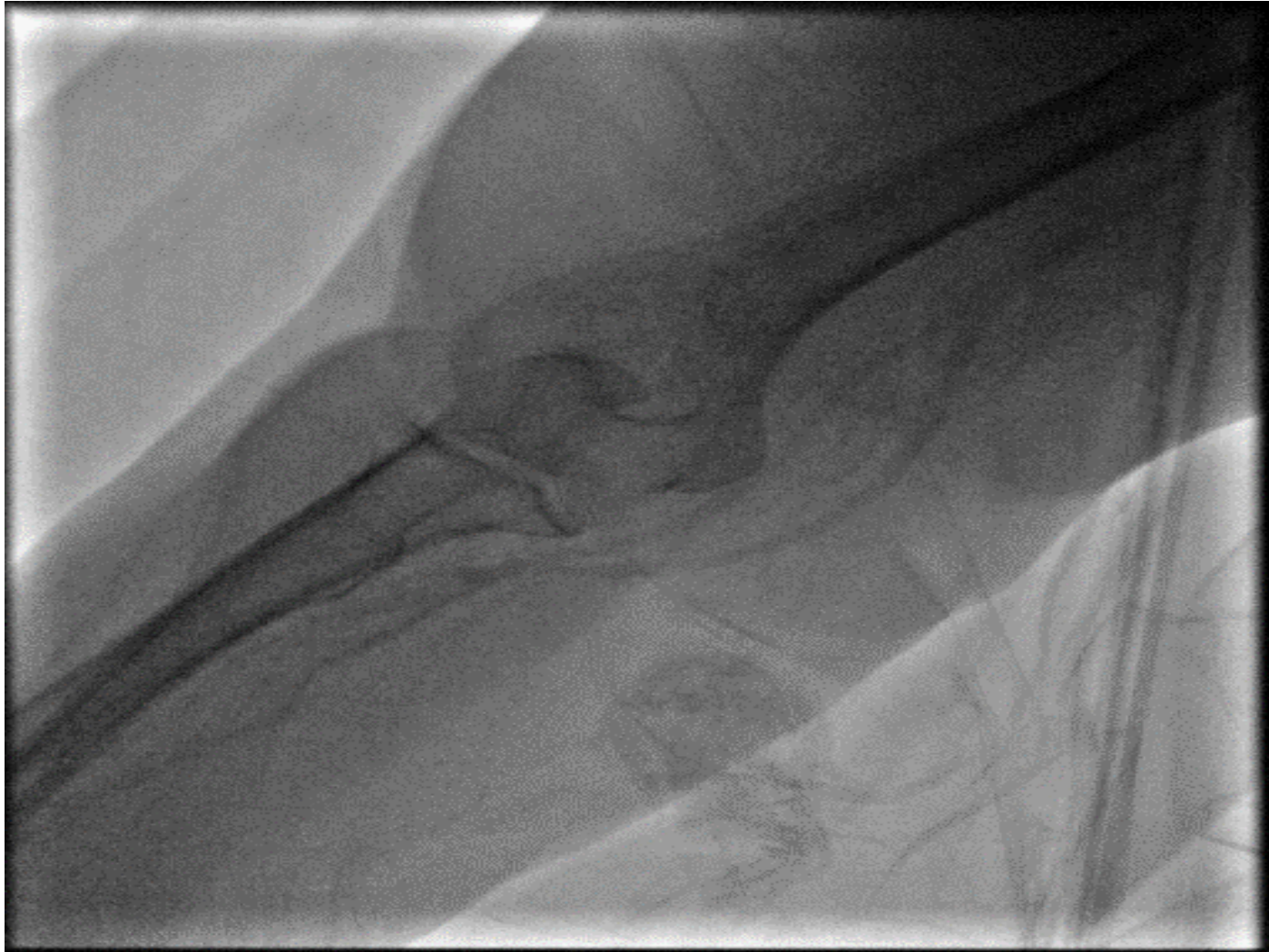
Figure 2. Dissection of the Ascending Aorta

(A) Cross-sectional transesophageal echocardiographic and (B) angiographic images (yellow arrows delineate the spiral dissection).

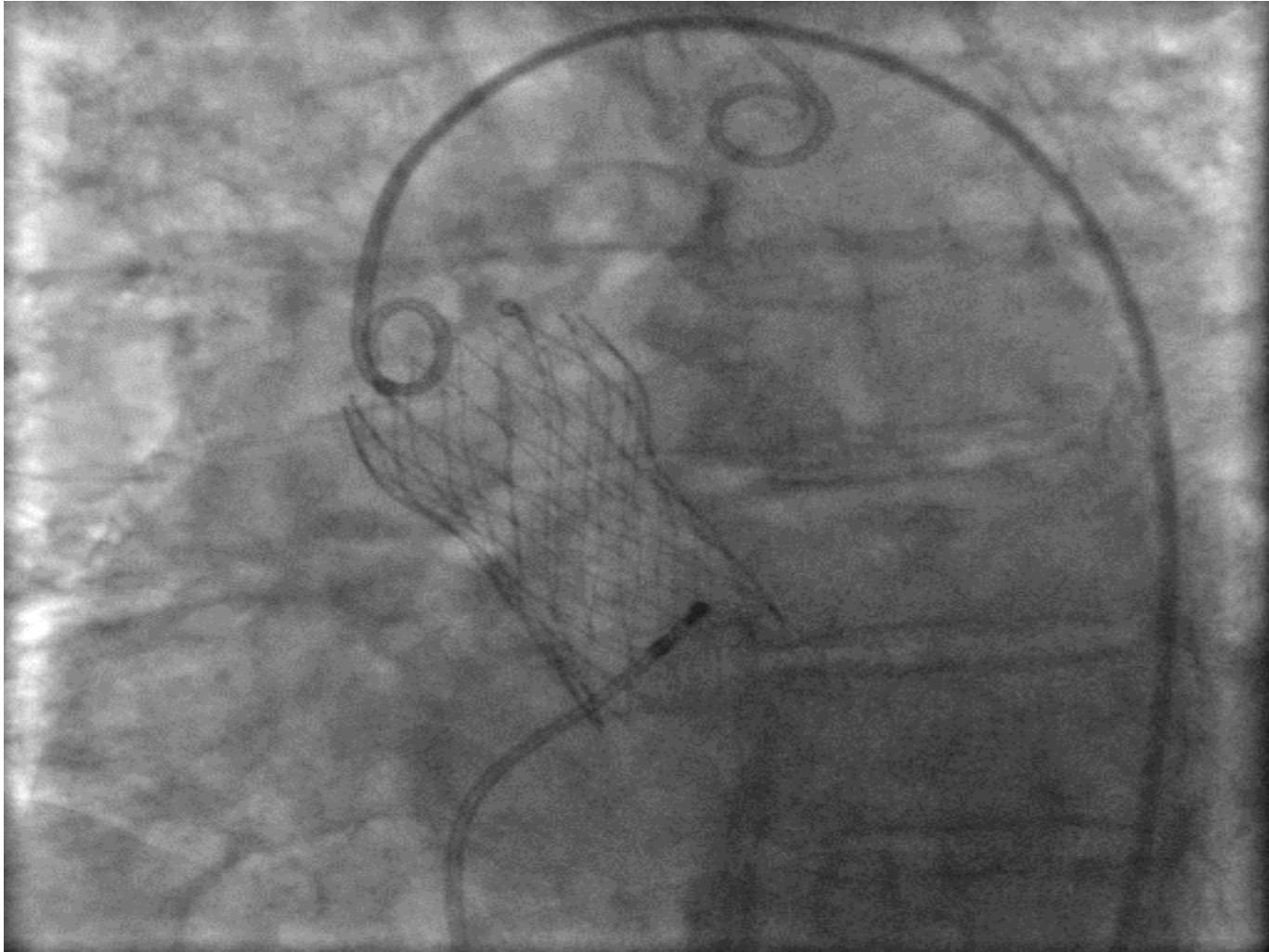
Femoral bleeding after puncture (16)



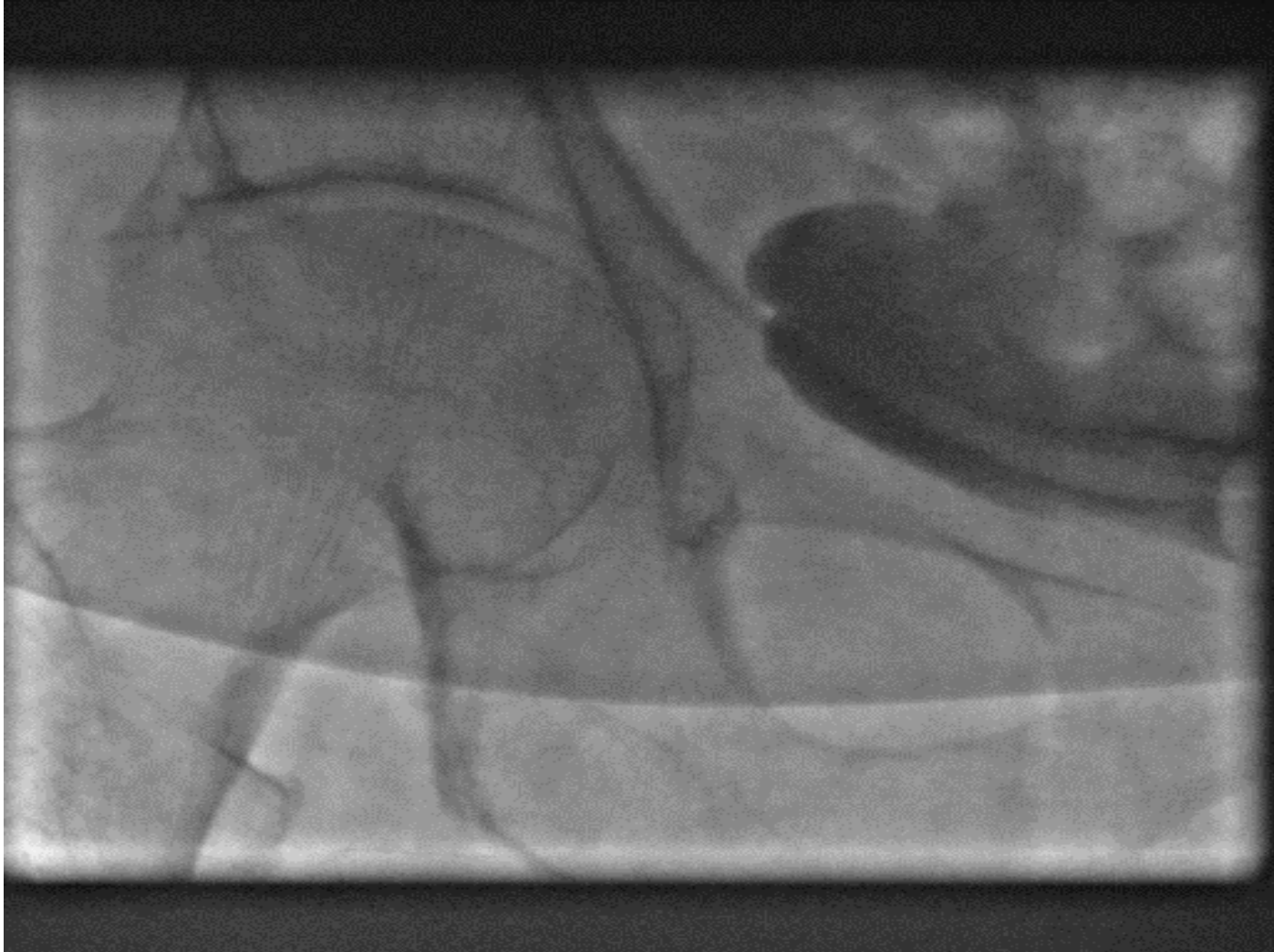Femoral bleeding after puncture (17) – Use of RA



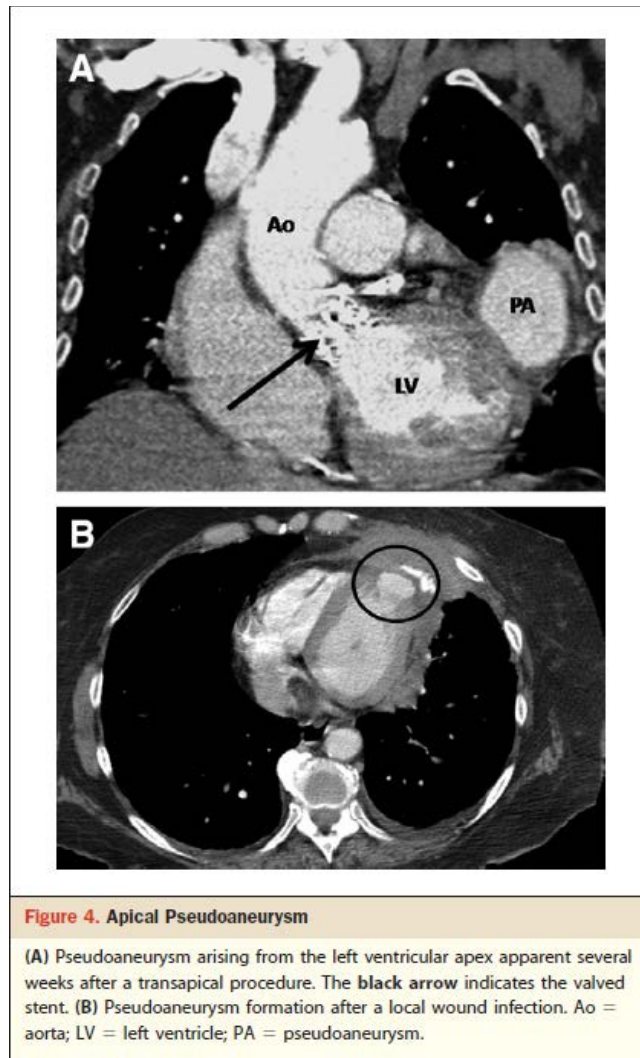
Femoral bleeding after puncture (18) – LFA for valve delivery



Femoral bleeding after puncture (19)



TAVI Transapical Complications



TAVI Mitral Valve Injury

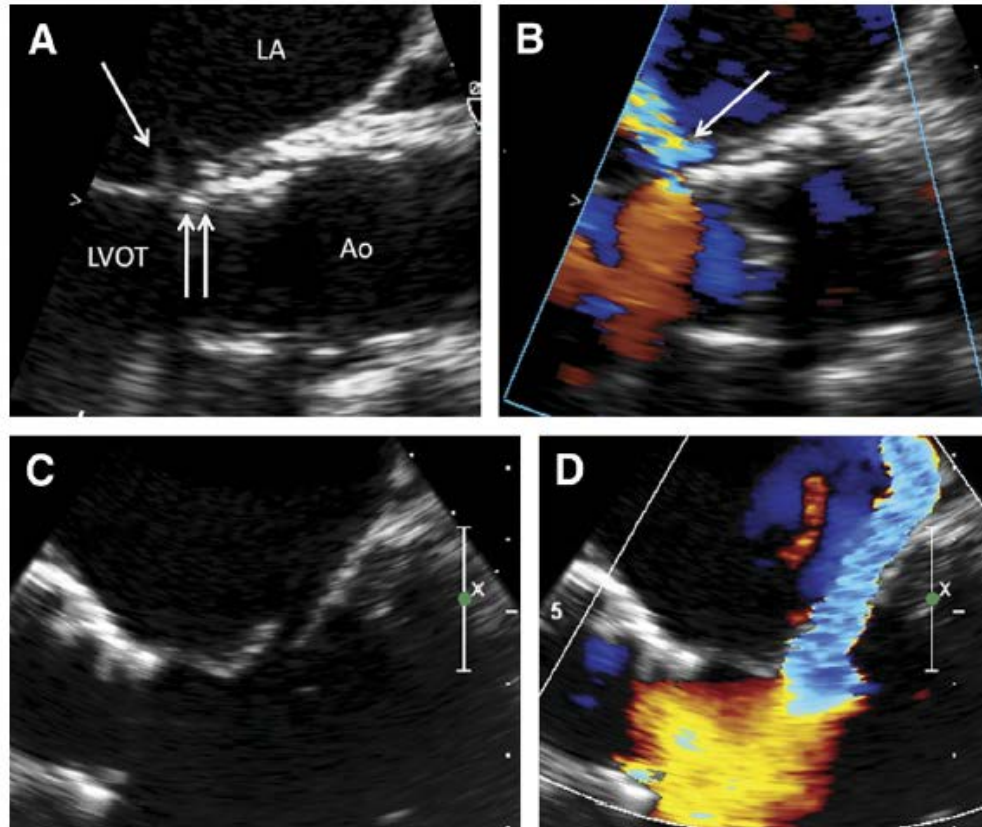


Figure 8. Delayed Mitral Valve Injury

(A) The stent (**double arrow**) is in contact with the anterior mitral leaflet. Prosthetic valve endocarditis 1 year after implantation associated with perforation of the mitral leaflet at the point of contact (**single arrow**). (B) Ensuing severe mitral regurgitation. (C) In a second patient, prolapse of the anterior mitral leaflet secondary to chordal rupture created (D) severe mitral regurgitation several months after the procedure. Ao = aorta; LA = left atrium; LVOT = left ventricular outflow tract.

TAVI Paravalvular Regurgitation

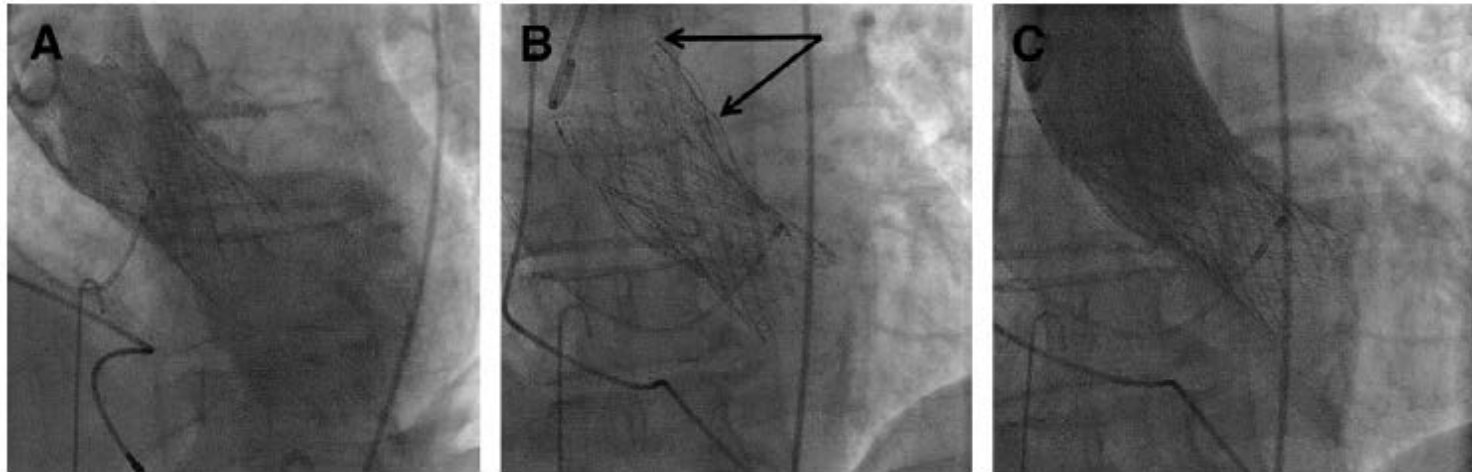
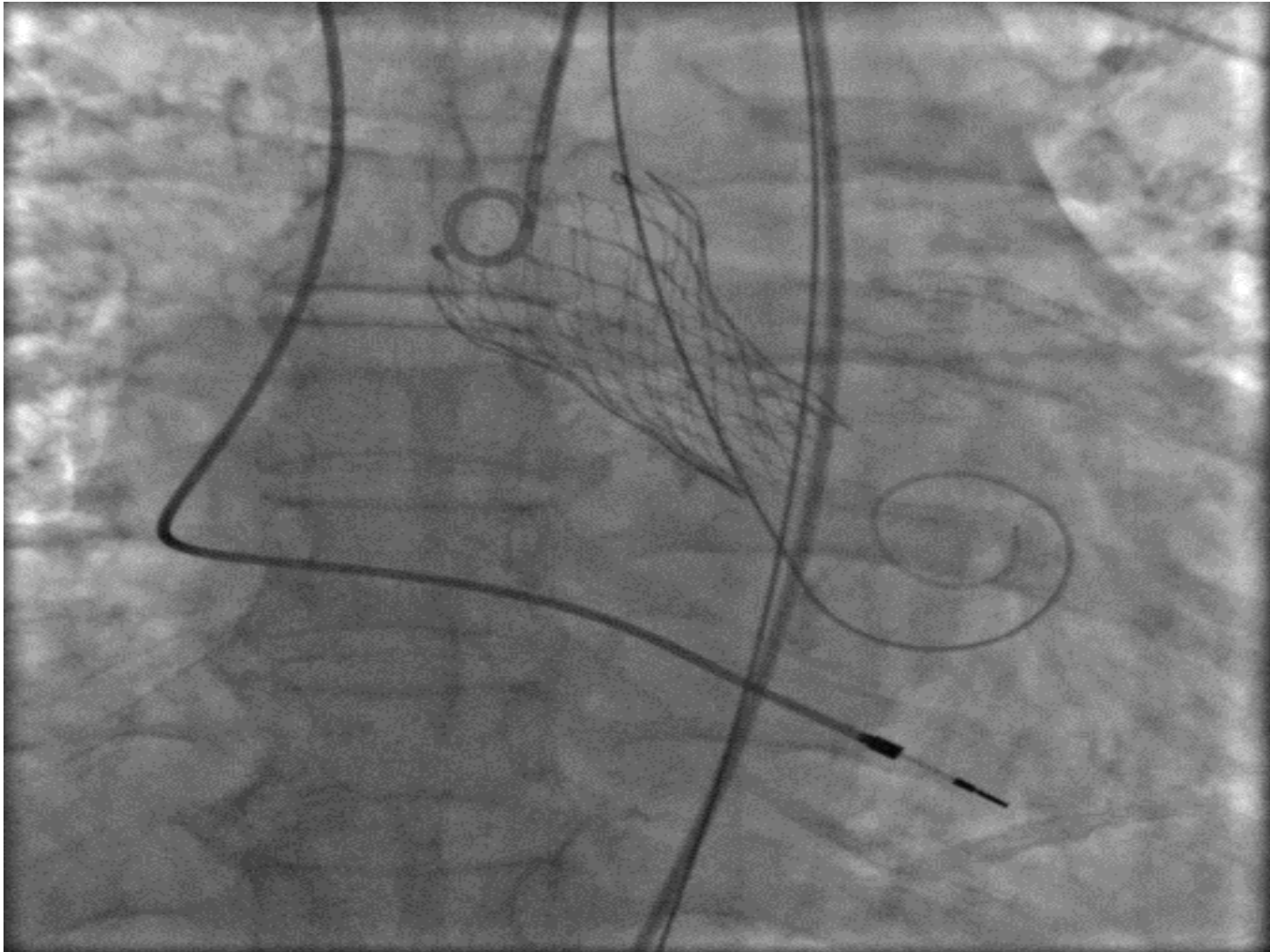


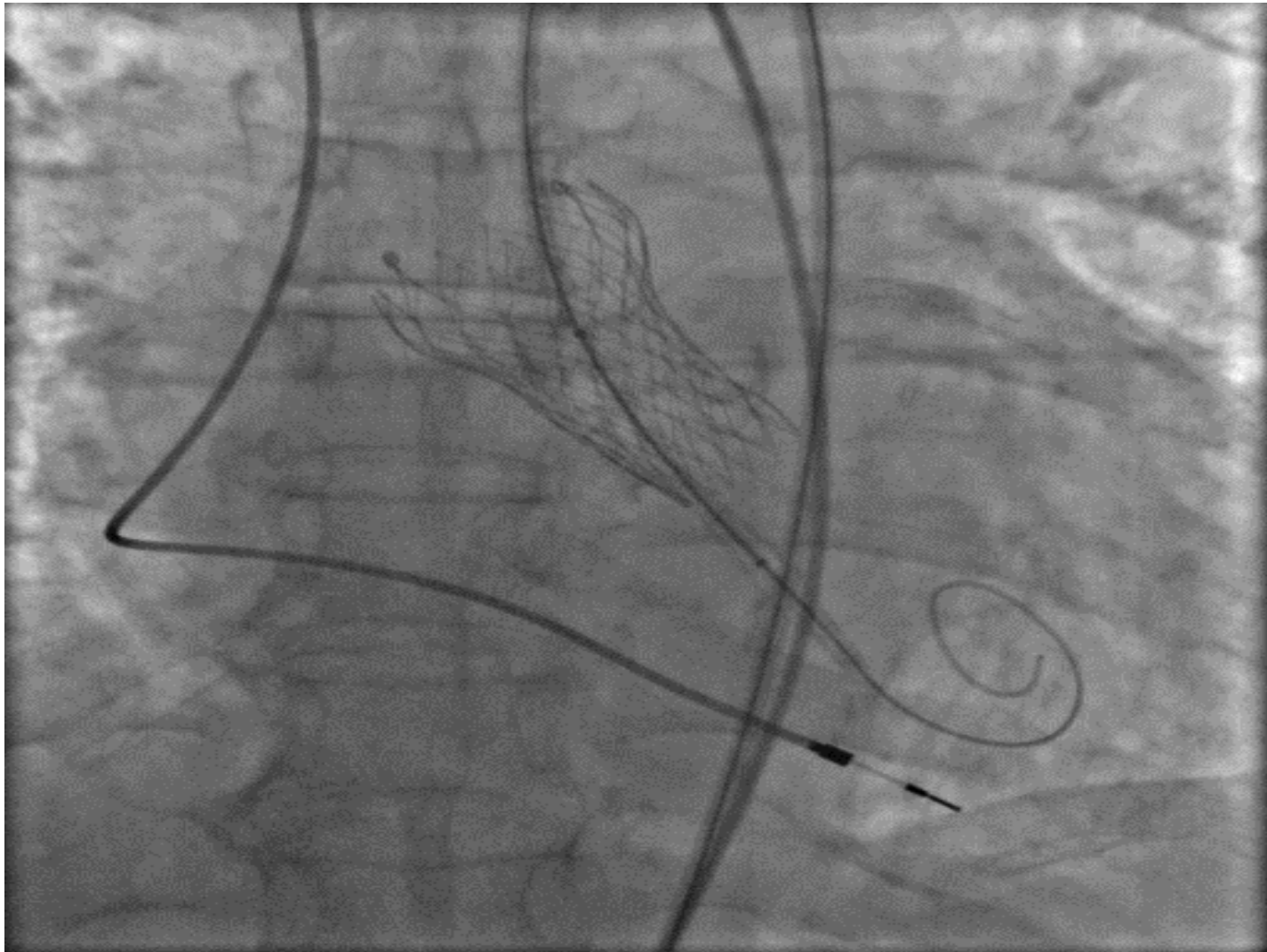
Figure 9. Paravalvular Regurgitation

(A) Self-expanding valve implanted too low, resulting in severe paravalvular regurgitation. (B) A second prosthesis was implanted in the correct position (arrows indicate the distal edge of both prostheses). (C) Mild residual paravalvular leak.

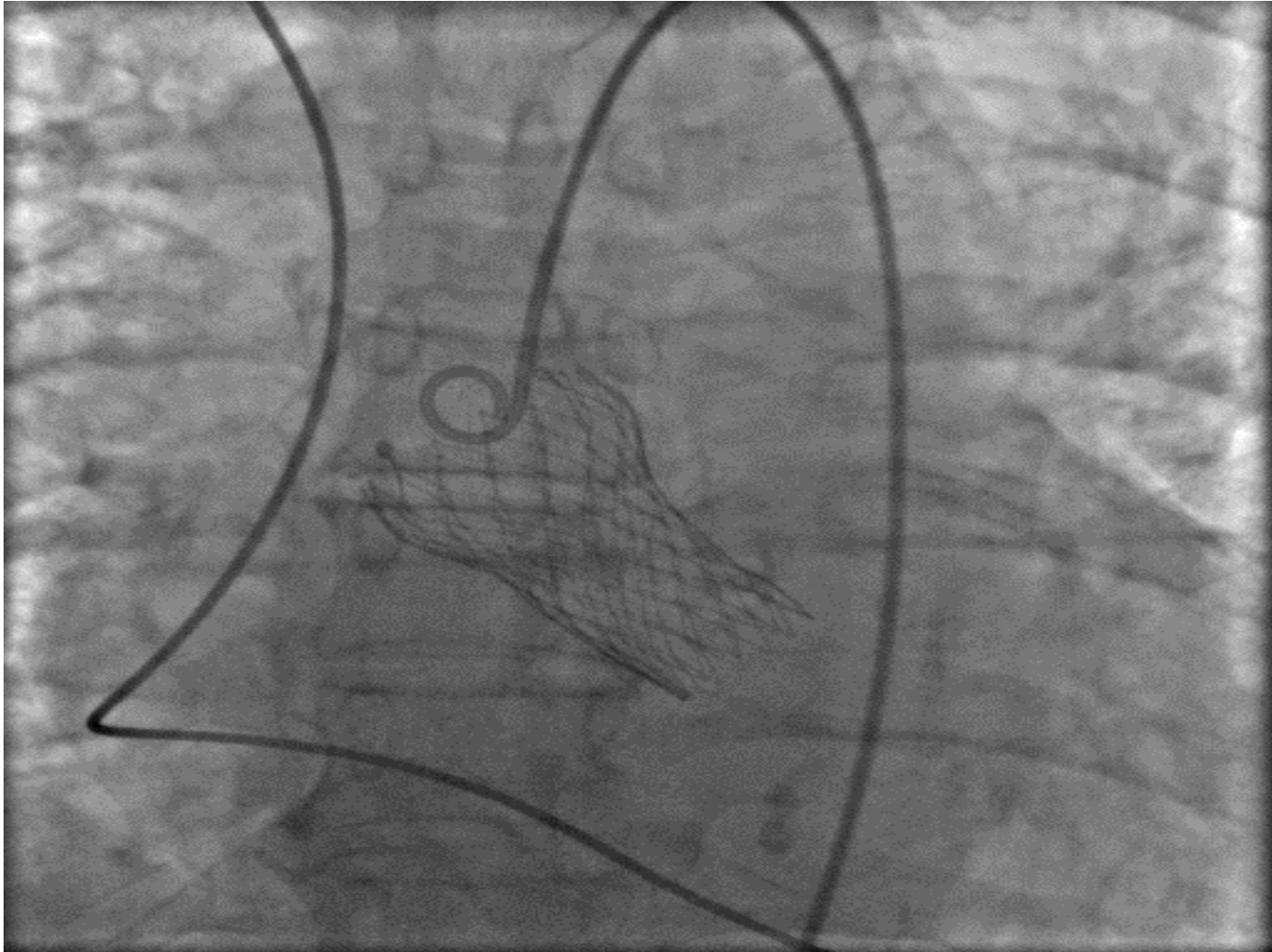
Paravalvular leak due to inadequate stent expansion (20)



Paravalvular leak due to inadequate stent expansion (21)



Paravalvular leak due to inadequate stent expansion (22)



TAVI Annulus Rupture

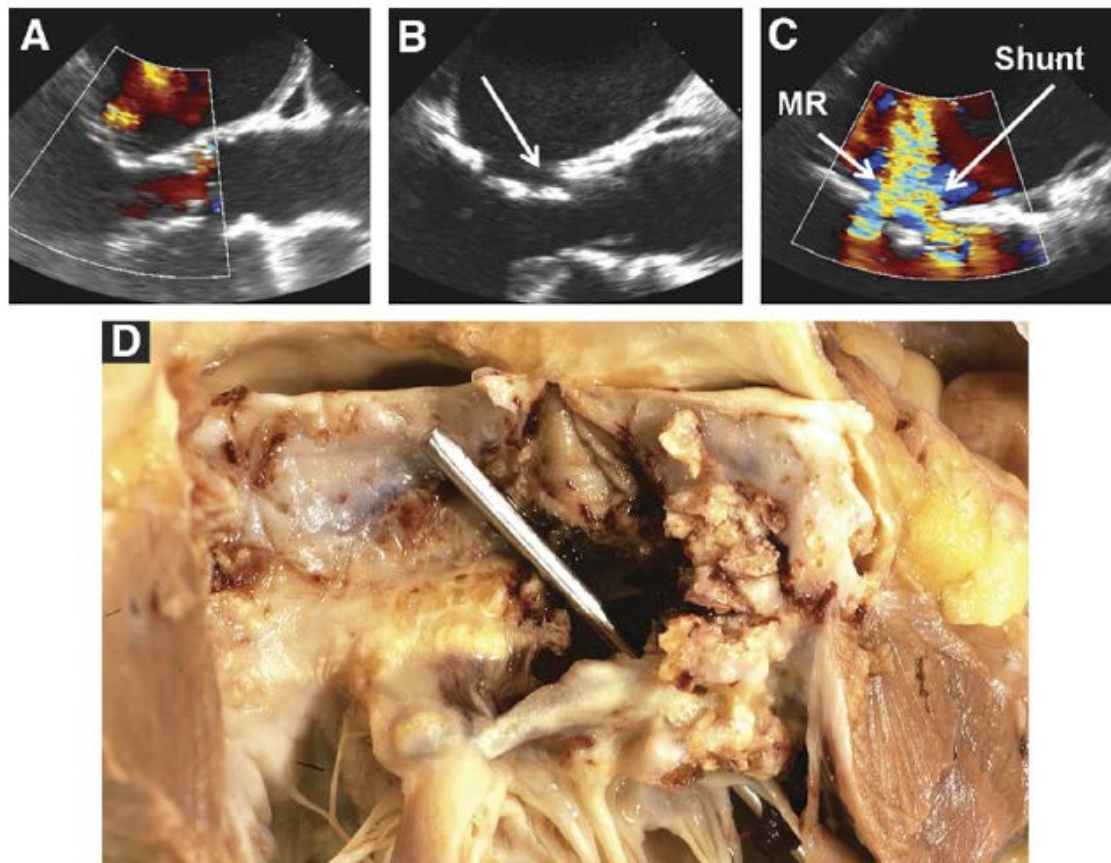


Figure 11. Annulus Rupture

(A) Pre-implantation significant mitral regurgitation (MR) and severe calcification of the aortic annulus and subvalvular tissues. (B and C) After valve implantation, a tear (arrows) is visible at the ventricular edge of the stent, connecting the left ventricular outflow tract and left atrium, with large left ventricular to left atrial shunt. (D) Autopsy proven tear of the anterior mitral curtain.

TAVI Coronary Obstruction

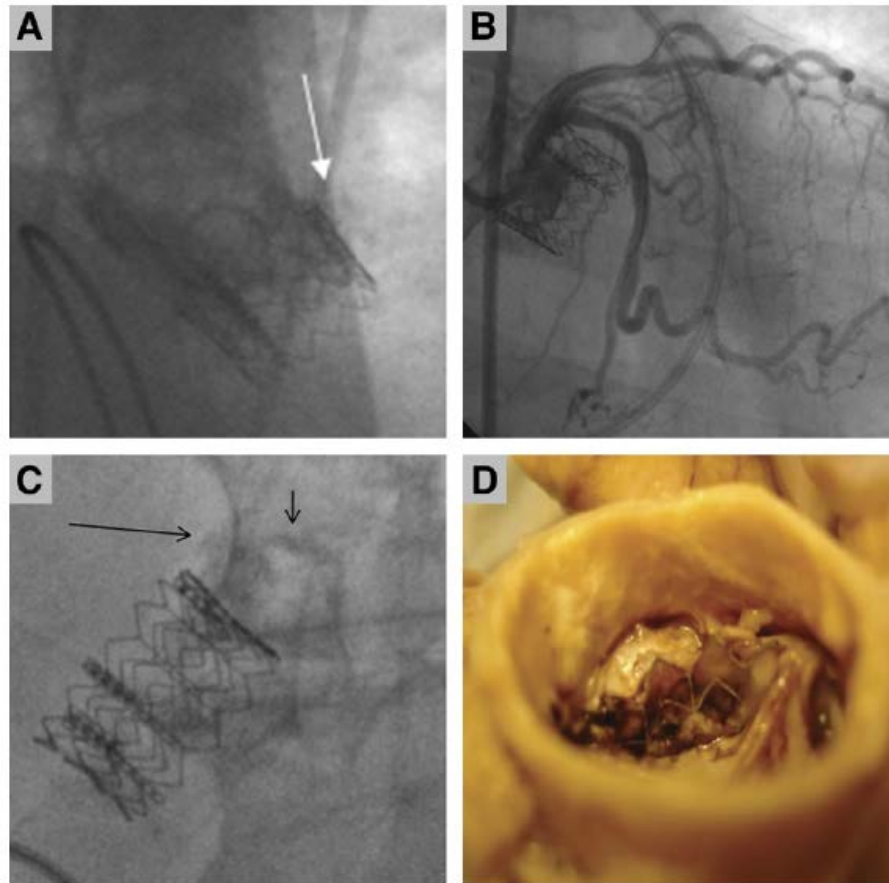


Figure 7. Left Main Obstruction

(A) Left main coronary artery occlusion resulting from a bulky leaflet displaced over the ostium. (B) Successful percutaneous intervention restored left coronary flow. (C) In a second patient, calcifications from the native aortic leaflet and left main (arrows) are approximated after valve implantation. (D) At autopsy, the leaflet (not the stent itself) seemed to obstruct the ostium.

Conclusions

- TAVI indication for severe aortic stenosis is currently for patients with high-risk and intermediate risk >75 years for surgical aortic valve replacement
- Technology is rapidly growing minimizing paravalvular leak and vascular complications due to reduced sheath size
- It is anticipated over the next years to be implemented in the majority of intermediate risk patients provided proven duration of the bioprosthetic valve